

ENTEROGENOUS CYST OF THE POSTERIOR FOSSA: A CASE REPORT

Quiste enterógeno de la fosa posterior: Reporte de caso

JOSÉ LEÓN P.^{1a}, FERNANDO ROMERO F.^{2a}, EUTEMIO MEDINA M.^{2b}, DIANA RIVAS F.^{3c}, LUIS ANTONIO T.^{2b}

¹Department of Neurosurgery of the Cayetano Heredia National Hospital, Lima, Peru. ²Department of Neurosurgery and

³Department of Neuropathology of the National Institute of Neurological Sciences, Lima, Peru.

^a Resident of Neurosurgery, ^b Neurosurgeon, ^c Neuropathologist

ABSTRACT

Introduction: The intracranial enterogenous cyst is a benign cystic tumor lesion of very rare frequency worldwide. These cysts can occur at any level of neuroaxis and their malignant transformation is rare. The case of a 32-year-old woman with a cystic lesion in the posterior fossa at the level of the occipitocervical junction is presented.

Clinical case: A 32-year-old woman with a history of tumor surgery in the posterior fossa 4 years ago, with a clinical picture of chronic headache and quadriplegia. The magnetic resonance imaging of the occipitocervical junction showed a cystic lesion at the level of the posterior fossa. A suboccipital craniotomy was performed with removal of the posterior arch of C1 and excision of the tumor. The histopathological study confirmed the diagnosis of enterogenic cyst.

Conclusion: The enterogenic cyst of the nervous system is an uncommon, benign pathology that can recur. The definitive diagnosis will be made by biopsy of the tumor piece.

Keywords: Cysts, Biopsy, Craniotomy, Central Nervous System, Headache Disorders (source: MeSH NLM)

RESUMEN

Introducción: El quiste enterógeno intracraneal es una lesión tumoral quística benigna de muy poca frecuencia a nivel mundial. Estos quistes pueden presentarse en cualquier nivel del neuroaxis y su transformación maligna es poco frecuente. Se presenta el caso de una mujer de 32 años con una lesión quística en fosa posterior a nivel de la unión occipitocervical.

Caso clínico: Mujer de 32 años con antecedente de cirugía tumoral en fosa posterior hace 4 años, con cuadro clínico de cefalea crónica y cuadriplejía. La imagen de resonancia magnética de la unión craneocervical evidenció una lesión de tipo quística a nivel de la fosa posterior. Se realizó una craneotomía suboccipital con retiro del arco posterior de C1 y exéresis del tumor. El estudio histopatológico confirmó el diagnóstico de quiste enterógeno.

Conclusión: El quiste enterógeno del sistema nervioso es una patología infrecuente, benigna y que puede recidivar. El diagnóstico definitivo se hará mediante la biopsia de la pieza tumoral.

Palabras Clave: Quistes, Biopsia, Craneotomía, Sistema Nervioso Central, Cefalea (fuente: DeCS Bireme)

Peru J Neurosurg 2020, 2 (1): 23-26

The enterogenous cyst of the central nervous system is a very rare benign endodermal lesion that in most cases its location is spinal^{1, 2}. These lesions result from displaced elements of the alimentary canal and are commonly found in the posterior mediastinum. These cysts can occur at any level of neuroaxis from the posterior clinoid to the coccygeal region; they are frequently found in the lower cervical and upper thoracic region.^{3,4,5,6}

Enterogenic or enteric cysts are benign lesions of low prevalence and their malignant transformation is very rare. They commonly affect children and young adults with slow growth, but with a tendency to recurrence.^{7, 8}

The case of a 32-year-old patient with a cystic lesion in the posterior fossa at the level of the craniocervical junction that radiologically suggested epidermoid cyst is presented.

Submitted : December 10, 2019

Accepted : December 28, 2019

HOW TO CITE THIS ARTICLE: León J, Romero F, Medina E, Rivas D, Antonio L. Enterogenous cyst of the posterior fossa: a case report. *Peru J Neurosurg* 2020; 2(1): 23-26

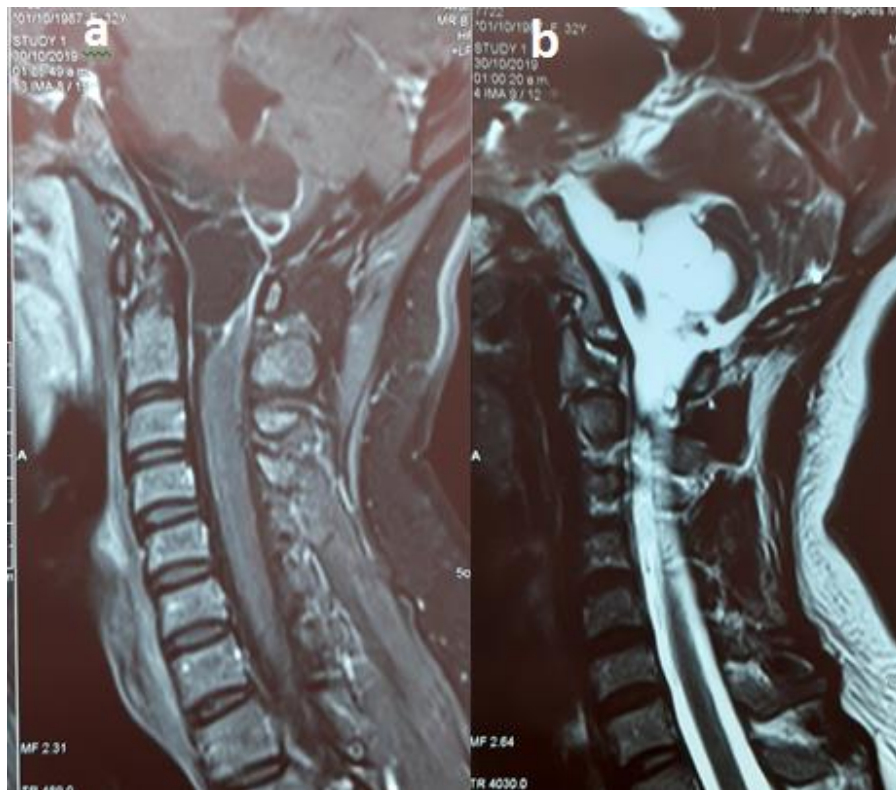


Fig 1. (A) Magnetic resonance, T1 sequence with contrast, hypointense lesion with well-defined contrast-enhanced borders is visible, in the region of the occipito-atloid junction. **(B)** Magnetic resonance sequence T2, hyperintense image can be seen that exerts mass effect on the brainstem and medulla at the occipitocervical junction.

However, the definitive histological study proved to be an enterogenous cyst.

CLINICAL CASE

History and examination: A 32-year-old woman, resident in Lima, with a history of surgical resection of a craniocervical junction cyst, hospitalized for a month, six years ago in the USA and discharged without neurological sequelae. He started a disease two years before admission with occipital headache of mild intensity and irradiation to the cervical region that partially remitted with analgesics. Symptoms increased progressively in the last 6 months with moderate headache and dizziness. A day before admission pain intensified and was associated with urinary retention so she went to the emergency area of our hospital.

The examination showed a marked decrease in strength in the four extremities and paresthesia below the cervical level, patient was awake, oriented in time, space and person, with tetraplegia, hypotonia, hyperreflexia, positive Babinski sign and anal and urinary sphincter disorder.

Treatment: During her pre-surgical stay, her clinical evolution was stationary. On the eighteenth day of his admission she underwent a suboccipital craniotomy with removal of the posterior arch of C1 and excision of tumor which was sent for histopathological study.

Evolution: The post-surgical evolution was slowly favorable while remaining hospitalized for a period of 40 days. She presented a urinary tract infection due to Klebsiella

pneumoniae, which he sent with antibiotic treatment, subsequently being the negative culture.

At discharge, she presented an improvement in quadriparesis motor deficit to brachial predominance (2/5) with persistence of sphincter disorder. Magnetic resonance imaging in T2 sequence showed a hyperintense lesion of multilobed cystic appearance that occupied the region of the craniocervical junction (Fig. 1). The histopathological study showed connective tissue with the presence of cyst upholstered by columnar epithelium with "Goblet" cells (Fig. 2).

DISCUSSION

Neurogenic or neuroenteric cysts are rare benign pathologies. Gauden et al, described 140 patients with the diagnosis of intracranial neuroenteric cyst since 1952. In China, two retrospective studies reported that enteric cysts of the central nervous system corresponded approximately 0.15% to 0.35% of all intracranial tumors.¹

This report describes a lesion located in the posterior fossa at the level of the craniocervical junction. The most frequent location is in the spinal cord 7 although cases have also been described in the posterior fossa^{10, 11} in the pontocerebellar angle^{11, 12}, in the supratentorial region^{12, 13} and in the foramen magnum.¹⁴

In our report a rare pathology is detailed; the MRI study does not have a very high sensitivity for diagnosis because there are much more frequent differential

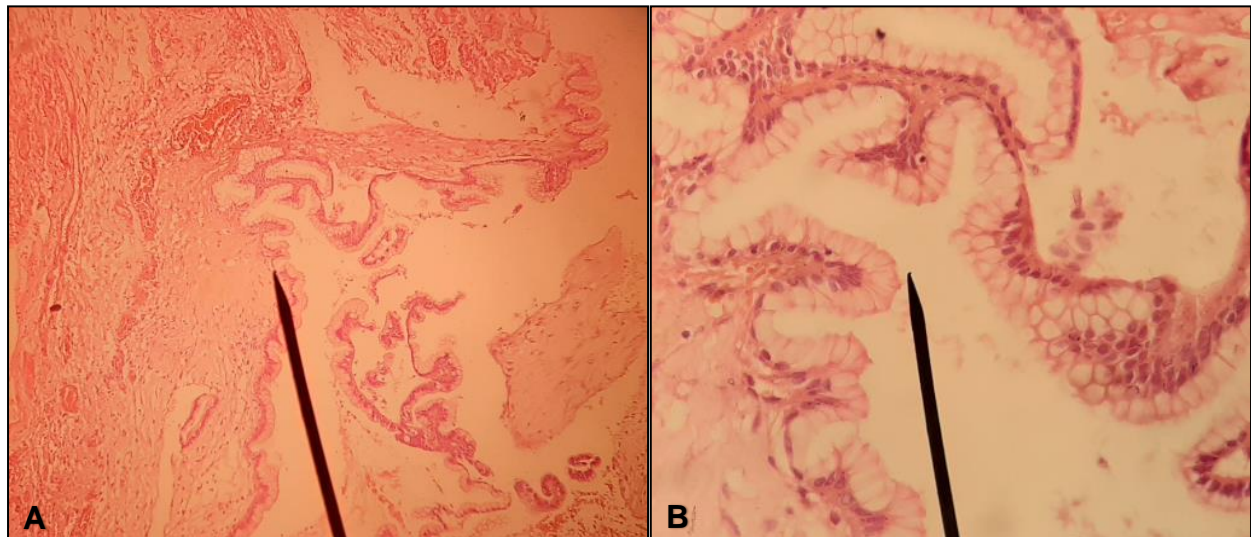


Fig 2. (A) Cystic wall of tumor is observed. **(B)** Monostratified epithelium of mucinous cells or "Goblet cells" of intestinal epithelium type is observed without cytological or architectural alterations. HE staining.

diagnoses. Enterogenous cysts usually appear isointense or hypointense in T1 and hyperintense in the T2 sequence.

Santos de Oliveira ET al.¹⁵, in his study describes 62.5% of hypointense images in T1 and 68.75% of images weighted hyperintense in T2.

Surgical treatment remains the treatment of choice. As Vasquez ET al.¹⁶ reports, these cysts can relapse, so that total resection must be achieved in all cases, an objective that is achieved with complete resection of the cyst wall.

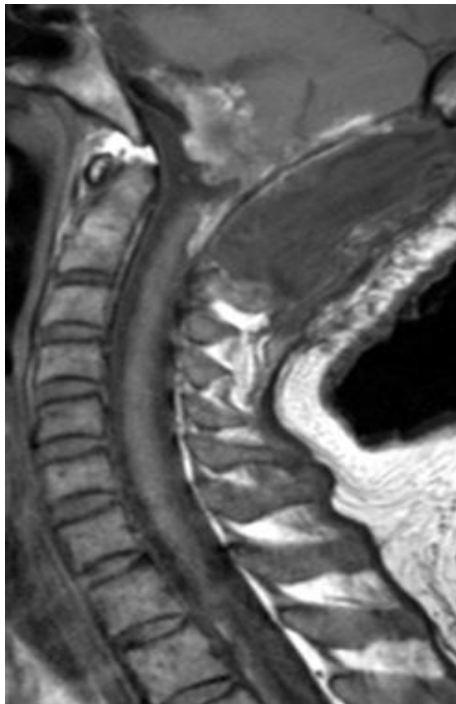

Fig 3. Postoperative Magnetic Resonance Imaging in T1 sequence in which an absence of cystic tumor lesion at the level of the occipitocervical junction is showed.

CONCLUSION

The Enterogenous Cyst of the nervous system is a rare, benign pathology that can recur in the patient. The treatment of choice is surgical and the definitive diagnosis will be made by biopsy of the tumor piece.

THANKS:

To Mr. Esteban, from the National Institute of Neurological Sciences for his valuable support in this study.

REFERENCES

1. Gauden AJ, Khurana VG, Tsui AE, Kaye AH. Intracranial neuroenteric cysts: a concise review including an illustrative patient. *J Clin Neurosci.* 2012 Mar;19(3): 352-9.
2. Osborn AG, Preece MT. Intracranial cysts: Radiologic - pathologic correlation and imaging approach. *Radiology* 2006; 239:650-4.
3. Agnoli AL, Laun A, Schonmayr R: Enterogenous intraspinal cysts. *J Neurosurg* 61:834-840, 1984.
4. Batson RA, Scott MR: Neurenteric cysts, Teratomatous Cysts, Teratomas, Giant Hairy nevi, and their associated anomalies, in Hoffman HJ, Epstein F (eds): **Disorders of the Developing Nervous System.** Diagnosis and Treatment. Boston: Blackwell Scientific Publications, 1986, Vol 41, pp 733-743.
5. Odake G, Yamaki T, Naruse S: Neurenteric cyst with meningocele. Case report. *J Neurosurg* 45:352-356, 1976.
6. Puusepp M: Variété rare de tératome, sous-dural de la région cervicale (intestinome): Quadriplégie, extirpation, guérison complète. *Rev Neurol* 2:879-886, 1934.
7. Holmes GL, Trader S, Ignatiadis P. Intraspinal enterogenous cyst. A case report and review of pediatric cases in the literature. *Am J Dis Child* 1879; 132:906-908.
8. LeDoux MS, Faye-Peterson OM, Aronin PA, et al. Lumbosacral neurenteric cyst in an infant. *J Neurosurg* 1993;78:821-825.
9. Mendel E, Lese GB, Gonzalez-Gomez I, et al. Isolated lumbosacral neurenteric cyst with partial sacral agenesis:

- case report. **Neurosurgery** 1994;35:1159-1163.
10. Rossi A, Cama A, Piatelli G, et al. Spinal dysraphism: MR imaging rationale. **J Neuroradiol** 2004;31:3-24.
 11. Vaishya S, Ramesh T. Spontaneous relapsing and recurring large multiloculated posterior fossa enteric cyst. **Acta Neurochir (Wien)** 2006;148:985-988.
 12. Mann KS, Khosla VK, Gulati DR, et al. Spinal neurenteric cyst. Association with vertebral anomalies, diastematomyelia, dorsal. **Surg Neurol** 1984, 21: 358-362
 13. Lee SH, Dante SJ, Simeone FA, et al. Thoracic neurenteric cyst in an adult: case report. **Neurosurgery** 1999; 45:1239-1243.
 14. Sharma RR, Ravi RR, Gurusinghe NT, Coutinho C, Mahapatra AK, Sousa J, et al: Cranio-spinal enterogenous cysts: clinico-radiological analysis in a series of ten cases. **J Clin Neurosci** 8:133-139, 2001.
 15. Ricardo Santos De Oliveira, M.D., Giuseppe Cinalli, M.D., Thomas Roujeau, M.D., Christian Sainte-Rose, M.D., Alain Pierre-Kahn, M.D., And Michel Zerah, M.D. Neurenteric cysts in children: 16 consecutive cases and review of the literature. **J Neurosurg** (6 Suppl Pediatrics). 2005; 103: 512-523.
 16. Pedro Vázquez Soto, Arturo Ruiz-Aburto A, Alfredo Yáñez Lermanda, Facundo las Heras, Gonzalo Miranda4. Quiste neuroenterico supratentorial: Reporte de un caso. **Rev. Chil. Neurocirugía.**2018; 44: 48-51.

Disclosures

The authors report no conflict of interest concerning the materials or methods used in this study or the findings specified in this paper.

Author Contributions

Conception and design: All the authors. *Drafting the article:* León. *Critically revising the article:* León, Romero, Rivas, Antonio. *Reviewed submitted version of manuscript:* León. *Approved the final version of the manuscript on behalf of all authors:* León.

Correspondence

Luis Antonio Toledo. Department of Neurosurgery. National Institute of Neurological Sciences. 1271 Ancash Street. Barrios Altos. 15003. Lima Peru. E-mail: Antoniotoledo75@hotmail.com