

ENDOVASCULAR MANAGEMENT OF NON-RUPTURED INTRACRANIAL ANEURYSMS WITH FLOW DIVERTER DEVICES. FIRST EXPERIENCE IN PERU

Manejo endovascular de aneurismas intracraneales no rotos usando diversores de flujo. Primera experiencia en el Perú

GIANCARLO SAAL-ZAPATA^{1a}, WALTER DURAND^{1a}, RICARDO VALLEJOS^{1a}, DANTE VALER^{1a}, JESÚS FLORES^{1a}, RODOLFO RODRIGUEZ^{1a}.

¹Department of Neurosurgery, Section of Neuroradiology, Guillermo Almenara Irigoyen National Hospital, Lima, Perú.
^aNeurosurgeon

ABSTRACT

Introduction: Endovascular treatment of non-ruptured intracranial aneurysms with flow diverter devices is a technique that currently has many indications for its use.

Objectives: Determine the clinical characteristics of patients, angiographic characteristics of the aneurysms, occlusion rate at 6 months and 1 year follow-up and complications associated to the deployment of flow diverter devices in the treatment of non-ruptured intracranial aneurysms.

Methods: We present a retrospective review of consecutive cases treated with flow diverters at our institution.

Results: Since October 2012 to April 2017, twenty-one patients were treated with a total of 29 non-ruptured aneurysms. Twenty six aneurysms (90%) were located in the anterior circulation and three aneurysms were located in the posterior circulation (10%). We employed 22 flow diverters (SILK = 9, FRED = 13). Fifty percent of the aneurysms were located in the paraclinoid segment of the internal carotid artery, followed by 28% located in the cavernous segment.

Globally, fifty eight percent of the patients were cured. There were three patients with persistence of the aneurysms and five complications: three carotid thrombosis, one migration and one mal-apposition of the stent. All this complications were and remain asymptomatic. Mortality rate in this series was zero percent.

Discussion: The use of flow diverter devices is a new technique for the treatment of non-ruptured intracranial aneurysms at our institution, with adequate rates of aneurysm occlusion.

Keywords: Intracranial Aneurysm, Stents, Cerebral Angiography. (source: MeSH NLM)

RESUMEN

Introducción: El tratamiento endovascular de los aneurismas intracraneales no rotos usando diversores de flujo es una técnica que en la actualidad tiene numerosas indicaciones para su uso.

Objetivos: Determinar las características clínicas de los pacientes, las características angiográficas de los aneurismas, la tasa de oclusión a los 6 meses y el 1er año, además de las complicaciones asociadas a la colocación de diversores de flujo en el tratamiento de aneurismas intracraneales no rotos.

Métodos: Presentamos una revisión retrospectiva de los casos consecutivos tratados con diversores de flujo en nuestra institución.

Resultados: Desde octubre 2012 hasta abril 2017 se trataron 21 pacientes con un total de 29 aneurismas intracraneales no rotos, de los cuales 26 aneurismas (90%) fueron del territorio anterior y 3 aneurismas se localizaron en circulación posterior (10%). Utilizamos 22 diversores de flujo (SILK = 9, FRED = 13). El 50% de los aneurismas se localizaron en el segmento paraclinoides de la carótida interna, seguido del 28% en el segmento cavernoso.

De manera global, el 58% de pacientes se curó, hubo 3 pacientes con persistencia de aneurismas y 5 complicaciones: 3 trombosis carotídeas, 1 stent migrado y 1 stent mal posicionado, todas asintomáticas. La mortalidad en la serie fue 0%.

Discusión: El uso de diversores de flujo es una técnica segura y efectiva para el tratamiento de aneurismas intracraneales no rotos en nuestra institución.

Palabras Clave: Aneurisma Intracraneal, Stents, Angiografía Cerebral. (fuente: DeCS Bireme)

Peru J Neurosurg 2019, 1 (3): 53-58

Submitted : May 06, 2019

Accepted : June 15, 2019

HOW TO CITE THIS ARTICLE: Saal-Zapata G. Endovascular management of non-ruptured Intracranial aneurysms with flow diverter devices. First experience in Peru. Peru J Neurosurg 2019; 1(3): 53-58

Intracranial aneurysms can be treated with various endovascular techniques: coils, balloon assisted coiling, stent assisted coiling, flow diverters and endosaccular devices such as WEB¹. Flow diverters are devices that reconstruct the parent artery by a mechanism called neoendotelization (endoluminal approach), unlike of endosaccular approaches (coils). Moreover, they promote a diverter effect redirecting the blood flow at the level of the intracranial aneurysm, causing thrombosis inside the aneurysm by estasis².

Initially, flow diverters had precise indications for their use, such as blister aneurysms, dysplastic/fusiform aneurysms, wide neck aneurysms, single or multiple aneurysms of the internal carotid artery in the cavernous and paraclinoid segment, also called carotid-ophthalmic aneurysms³. Posteriorly, published reports of their use in ruptured and dissecting aneurysms, middle cerebral artery, giant and posterior fossa aneurysms appeared⁴⁻⁷. The occlusion rate using flow diverters is high, reaching more than 90% in some series⁸.

The classic option is the craniotomy with clipping of the aneurysm in institutions where there is absence of adequate infrastructure, otherwise, the embolization is the treatment of choice and the most adequate technique will be chosen depending on the characteristics of the lesion⁹.

In our country the embolization is an expensive procedure and some institutions like the social security cover the totality of the expenses, nevertheless, no statistics exist regarding the treated patients.

We present the first series of consecutive cases treated with flow diverters in a Peruvian hospital. Moreover, we show representative cases treated at our institution

METHODS

Retrospective design study. A consecutive series of cases were analyzed between October 2012 and April 2017 at our institution.

Clinical charts and angiographic studies of the patients with diagnosis of non-ruptured intracranial aneurysms treated with flow diverters were analyzed. No informed consent was required because of the retrospective design. The procedures were performed in the angio-suite with a biplanar Phillips Allura angiograph.

In all cases, double antiaggregation therapy with aspirin and clopidogrel was initiated 5 days before the procedure. This double therapeutic regimen was continued for 6 months, suspending clopidogrel, then aspirin alone was continued for the first year. Angiographic controls were performed at 6-month and first year after the embolization.

RESULTS

From October 2012 to April 2017, twenty one clinical charts, operating records and angiographies of patients treated with flow diverters at Guillermo Almenara Nacional Hospital, EsSalud. These cases were analyzed (15 females and 6 males), with a total number of 29 aneurysms treated with 22 flow diverters.

Table 1 shows the characteristics of the patients and location of treated aneurysms. Female sex was predominant in this series with 71% compared to 29% in males. The age ranges between 28 – 70 years, with a mean age of 56 years and with the largest number of treated cases between 60 – 70 years. The most frequent symptom was headache.

Ninety percent of the aneurysms were found in the segments

Table 1. Characteristics of patients with non-ruptured intracranial aneurysms treated with flow diverter devices.

Characteristics	N (%)
Age*	56 (44 – 67)
Sex	
Female	15 (71%)
Male	6 (29%)
Flow diverter	
FRED	13 (59%)
SILK	9 (41%)
Symptoms	
Headache	10 (50%)
Incidental finding	5 (20%)
Ocular alterations	5 (20%)
Motor deficit	1 (10%)
Aneurysms localization	
Paraclinoid	14 (48%)
Cavernous	8 (28%)
Supraclinoid	4 (13.5%)
Posterior fossa	3 (10.5%)

*Mean and range

of the internal carotid artery territory, representing 26 cases and the remaining 10% was found in the vertebra-basilar territory (3 cases).

Paraclinoid segment aneurysms, also called carotid-ophthalmic aneurysms represented 50% of the cases. According to Barami classification, 70% of the aneurysms were found in the ophthalmic territory (type Ia and Ib) and 30% of the remaining aneurysms were found in the superior hypophysial artery (type III).

Twenty-two flow diverters were employed in 21 patients.

The most frequently used device was FRED flow diverter (13 cases), followed by SILK flow diverter (9 cases). Table 2 shows the type of aneurysms, type of flow diverter employed and the angiographic control results at 6-months and 1-year follow-up.

In patient 18, two flow diverters were deployed in the same vascular territory: she had a left posterior communicating aneurysm with a wide neck of 8,64 mm and a left carotid-ophthalmic, both of them were non-ruptured. At 6-months and 1-year follow-up both aneurysms persist but with a significative decrease in the inflow. A new angiographic

Table 2. Six-month and one year follow-up after treatment of unruptured aneurysms using flow diverter devices (FDD)

ID	Age/ Sex	Aneurysm location	FDD	6-months follow-up	1 year follow- up	Final result
1	70/M	Carotid cavernous	SILK	Cured		Cured
2	58/M	AICA	SILK		Cured	Cured
3	49/F	Carotid cavernous	SILK	Roy 3	Cured	Cured
4	62/M	Carotid cavernous	FRED		ICA thrombosis	ICA thrombosis
5	50/F	Superior hypophysial	FRED		Cured	Cured
6	49/F	Paraclinoid	SILK	Roy 3	Roy 2	Persistence of aneurysm
7	59/F	Carotid cavernous	FRED		Not cured	Migration of stent
8	28/M	Paraclinoid	FRED		Persistence of aneurysm	Persistence of aneurysm
9	69/F	Paraclinoid	FRED	-	Not cured	ICA thrombosis
10	38/F	Carotid cavernous	FRED	ICA thrombosis		ICA thrombosis
11	60/F	Carotid cavernous Superior hypophysial Posterior communicating	SILK		Cured	Cured
12	44/M	Paraclinoid Anterior choroidal	FRED	-	-	No control
13	37/F	Paraclinoid	FRED			Mal-apposition
14	35/F	Superior hypophysial	SILK		Cured	Cured
15	60/F	Paraclinoid Carotid cavum	SILK		Cured	Cured
16	63/M	Vertebral V4 segment	FRED	-	-	No control
17	32/F	Paraclinoid	SILK		Cured	Cured
18	48/F	Posterior communicating Paraclinoid	SILK FRED		Persistence of aneurysm	Persistence of aneurysm
19	46/F	Paraclinoid Superior hypophysial Posterior communicating Carotid cavum	FRED		Cured	Cured
20	58/F	Paraclinoid	FRED	Cured		Cured
21	32/F	Vertebral V4 segment	FRED		Cured	Cured

control will be necessary in 6 months, in this case we suggest to withdrawal antiaggregation therapy to promote thrombosis of the aneurysms.

Regarding the three treated posterior fossa aneurysms; a SILK flow diverter was used to treat a non-ruptured aneurysm of the right anterior inferior cerebellar artery (AICA). Regarding the vertebral aneurysms in V4 segment, the FRED flow diverter was employed. Only patients 2 and 21 could be controlled, both aneurysms were cured in their follow-up, obtaining a curation rate of 100% in the controlled posterior fossa aneurysms.

In five patients, multiple aneurysms were treated in the same vascular territory. We found 13 aneurysms, in patients 12, 15 and 18, two aneurysms were treated in each case. Patient 12 was not controlled, patient 15 was cured and patient 18 was the only one where two flow diverters were employed but at 6-months and 1-year follow-up the aneurysms still remain with decreased inflow, requiring subsequent controls.

In patient 11, three aneurysms were treated, at 1-year follow-up there is total absence of them. In patient 19, four aneurysms were treated, with absence of them at 1-year follow-up.

Of the five patients with multiple aneurysms treated with 1 flow diverter, a cure rate of 60% was achieved (3 patients), one patient has persistence of aneurysm and one patient was not controlled. In summary, nine multiple aneurysms were cured in three patients.

With regards to patient follow-up, we performed angiographic controls at 6-months to 5 patients (24% of total) and at 1-year to 16 patients (76% of total). Globally 90% of the patients were controlled (19/21), most of them at the first year after treatment.

At 6-months follow-up five patients were evaluated, two of them were cured (patient 1 and 20), one patient developed asymptomatic carotid thrombosis (patient 10) due to a mal-

apposition of the stent and continued with double aggregation therapy. In patient 3 we found persistence of the aneurysm and was catalogued as Raymod-Roy 3, posteriorly in the 1-year follow-up there was a total occlusion of the aneurysms. Patient 6 was catalogued as Raymod-Roy 3 at 6-months follow-up and then at 1-year follow-up it became Raymond-Roy 2, still requiring subsequent controls.

At 1-year follow-up, 16 patients were evaluated, 10 patients were cured (62%), we performed angiographic controls to two patients with residual aneurysms at 6 months (patients 3 and 6). Three patients still had persistence of aneurysms with decreased inflow, one of them at 6-months control was Raymond-Roy 3 and at 1-year control we found a Raymond-Roy 2 (patient 6). There were 3 patients that completely failed to treatment: two carotid thrombosis, a stent migration and a stent mal-apposition, all of them asymptomatic.

In general, 19 patients out of 21 were controlled, representing 90% of the cases, the total occlusion rate was 58%, represented by 11 patients (17 aneurysms). In three patients' aneurysms persisted (15%) and the complication rate was 26%, all asymptomatic (5 patients): three carotid thrombosis, a stent migration and a stent mal-apposition (Fig 1). The mortality of this series was 0%.

DISCUSSION

Flow diverters are endovascular devices that allow an endoluminal approach of the parent artery, allowing the redirection of the blood flow¹⁰. Since their introduction in 2007, their indications have increased. Initially they were employed in non-ruptured cases, nevertheless, reports of their use in ruptured aneurysms exist in the literature⁷. Currently, they can be used in most of wide neck aneurysms, fusiform, blister, paraclinoid, supraclinoid, middle cerebral artery, anterior cerebral artery, posterior fossa aneurysms and distal vessels.

Exist different types of flow diverters: the most widely used are the Pipeline Embolization Device (PED), SILK and

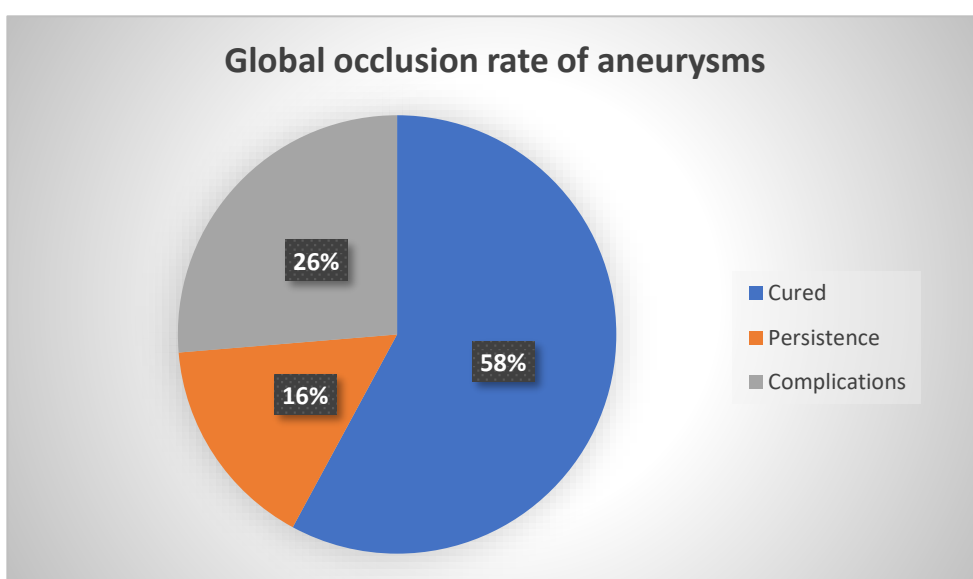


Fig 1. Global occlusion rate of aneurysms treated with flow diverter devices (FDD).

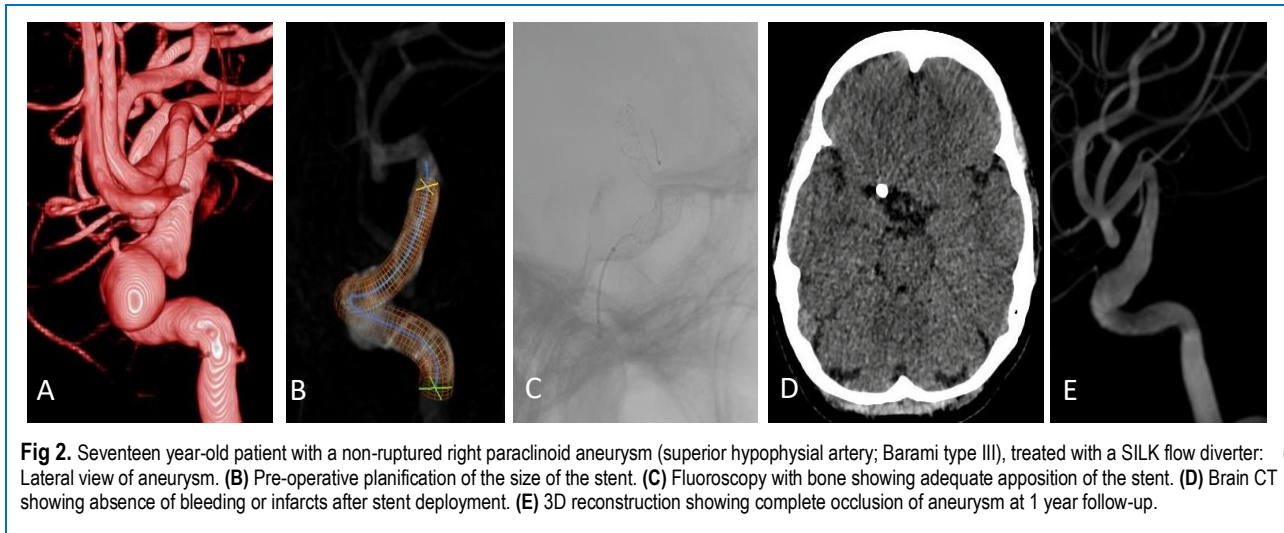


Fig 2. Seventeen year-old patient with a non-ruptured right paraclinoid aneurysm (superior hypophyseal artery; Barami type III), treated with a SILK flow diverter: (A) Lateral view of aneurysm. (B) Pre-operative planification of the size of the stent. (C) Fluoroscopy with bone showing adequate apposition of the stent. (D) Brain CT showing absence of bleeding or infarcts after stent deployment. (E) 3D reconstruction showing complete occlusion of aneurysm at 1 year follow-up.

FRED (Flow Redirection Endoluminal Device). Exist other devices such as Surpass and p64 (Phenox) but are less frequently used.

Multiple studies demonstrate the high occlusion rate of intracranial aneurysms using flow diverters, cataloguing this as a modern and effective technique if correctly indicated^{3,4,11}. In our series, anterior and posterior circulation aneurysms were found, with an occlusion rate within ranges similar to international studies.

In 2010, some studies reported the mechanism of action of flow diverters and their complications, at first they used two types: Pipeline Embolization Device (PED), approved by the FDA and with authorization for its use in the USA, and the SILK flow diverter, used in Europe. Wong et al mentioned intracerebral hemorrhage rates of 2% for Pipeline and 0,8% for SILK. In our study, we did not find this complications, they also report morbidity and mortality rates of 10% and 5% respectively¹².

Brinjikji et al performed a metaanalysis, demonstrating a 6-months occlusion rate of 76%, showing that occlusion rates are higher in aneurysms of less than 10 mm². Subarachnoid hemorrhage rate after flow diverter deployment was 3% and morbi-mortality was 5%. Moreover, they mention that 6% of the patients developed ischemic stroke, with large, giant and posterior fossa aneurysms associated with this complication^{2,13}.

In 2011, systematic reviews were published explaining the mechanism of action of the devices, like Urso et al. review, giving emphasis to the treatment of the diseased artery through the process of neoendotelization and reconstruction of the parent artery¹. Arrese et al. in 2012, demonstrated a total occlusion of 76,2% at 9-months follow-up using Pipeline, mortality and morbidity rates were 2,8% and 7,3% respectively¹⁴.

Shankar et al in 2012 treated 19 patients and 29 complex aneurysms with the SILK flow diverter, without concomitant treatment with coils, reaching a total occlusion rate of 59%, very similar to our results. Moreover, they report a morbidity and mortality rates of 10% and 5% respectively. This is the study that most closely resembles our results¹⁵.

Recently, Lozupone et al. published a study of 17 patients with subarachnoid hemorrhage due to aneurysm rupture

that were treated with flow diverters, with no re-rupture cases after treatment. Mortality and morbidity was 12% for both. Twenty one devices were employed, most of them Pipeline⁷.

Briganti et al in 2017 showed 7-year follow-up results with flow diverters in intracranial aneurysms, 90% of the cases were non-ruptured, with an occlusion rate of 91%, partial occlusion rate of 4%, parent artery occlusion 2%. They suggest that ischemic complications occur in a late period, particularly between 12 – 18 months¹⁶.

Indications for the use of flow diverters has increased, including cases of middle cerebral artery aneurysms with encouraging results (occlusion rate 80% and morbidity 4 – 10%).

Despite the fact that most the publications report a mortality rate between 0 to 10%, in our series mortality was 0%, morbidity rate was high, 26% compared to 5 -10% which is the mean in most of the series. These cases could be explained because they were the initial cases and the learning curve was initiating, posteriorly the complication rate diminished. Moreover, the complications in our series were asymptomatic.

In Peru, our institution was the first to employ flow diverters in patients with intracranial aneurysms. This is an expensive treatment and not all hospitals have the technology and trained staff to perform these procedures.

This study has limitations: the number of cases is small and the design is descriptive, so we could not be able to evaluate statistical associations. Moreover, the study was performed in a national reference hospital which receives complex cases and these cases cannot be generalized to other institutions.

CONCLUSION

The use of flow diverters is a safe and effective technique in the treatment of unruptured internal carotid artery aneurysms in its cavernous, paraclinoid and supraclinoid segments.

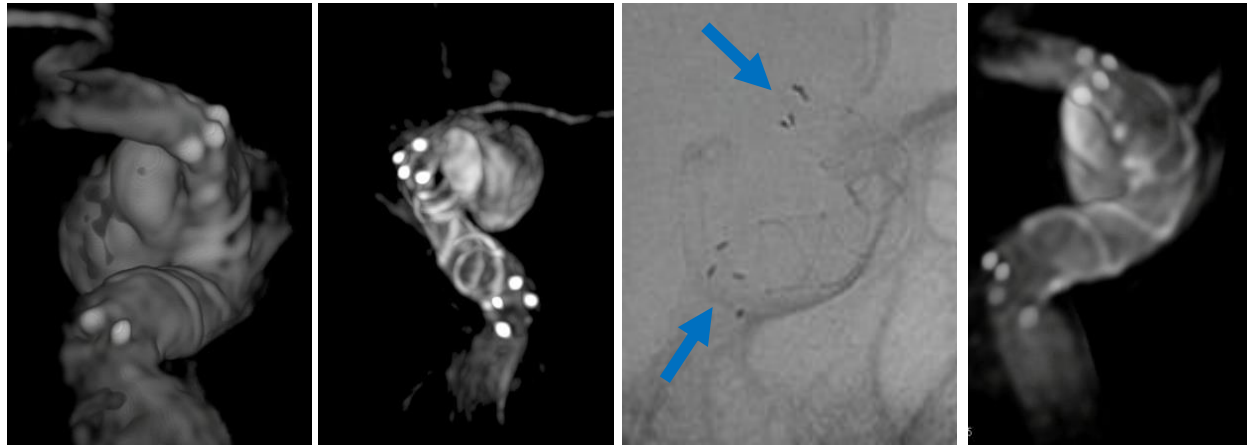


Fig 3. FRED flow diverter: the sequence of images shows adequate apposition of the stent in the proximal and distal edges of the internal carotid artery at cavernous and paraclinoid segments.

REFERENCES

1. Urso PID, Lanzino G, Cloft HJ, Kallmes DF. Flow Diversion for Intracranial Aneurysms. 2012;2363-2368. doi:10.1161/**STROKEAHA**.111.620328
2. Brinjikji W, Murad MH, Lanzino G, Cloft HJ, David F. Endovascular Treatment of Intracranial Aneurysms With Flow Diverters. 2013;442-447. doi:10.1161/**STROKEAHA**.112.678151
3. Gemmete JJ, Elias A. Endovascular Methods for the Treatment of Intracranial Cerebral Aneurysms. **Neuroimaging Clin NA**. 2013. doi:10.1016/j.nic.2013.03.007
4. Chen Z, Yang Y, Miao H, Tang W, Chen J. Endovascular treatment for large and giant fusiform aneurysms of the vertebrobasilar arteries. **J Clin Imaging**. 2013;37(2):227-231. doi:10.1016/j.clinimag.2012.05.002
5. Zhang Y, Zhou Y, Yang P, Liu J, Xu Y, Hong B. Comparison of the flow diverter and stent-assisted coiling in large and giant aneurysms : safety and efficacy based on a propensity score-matched analysis. 2015. doi:10.1007/s00330-015-4052-1
6. Cagnazzo XF, Mantilla XD, Lefevre XP, Dargazanli XC, Gascou XG, Costalat X V. Treatment of Middle Cerebral Artery Aneurysms with Flow- Diverter Stents: A Systematic Review and Meta-Analysis. 2017.
7. Lozupone E, Piano M, Valvassori L, et al. Flow diverter devices in ruptured intracranial aneurysms: a single-center experience. 2017;1-7. doi:10.3171/2016.11.**JNS**161937.
8. Endoluminal FR, Viejo A. Comparison of PED and FRED Flow Diverters for Internal Carotid Artery Aneurysms : A Propensity. 2018;0(0):1-7. doi:10.1093/neuros/nyy572
9. Yu SCH, Wong GKC, Wong JKT, Poon WS. Endovascular coiling versus neurosurgical clipping for ruptured intracranial aneurysms: significant benefits in clinical outcome and reduced consumption of hospital resources in Hong Kong Chinese patients. **Hong Kong Med J = Xianggang yi xue za zhi**. 2007;13(4):271-278. http://www.ncbi.nlm.nih.gov/pubmed/17592179. Accessed March 31, 2018.
10. Sfyroeras GS, Dalainas I, Giannakopoulos TG, Antonopoulos K, Kakisis JD, Liapis CD. Flow-diverting stents for the treatment of arterial aneurysms. **YMVA**. 2012;56(3):839-846. doi:10.1016/j.jvs.2012.04.020
11. Yavuz K, Ozer C, Geyik S. Treatment of Intracranial Aneurysms Using the Pipeline Flow-Diverter Embolization Device : A. 2012; (Fig 1).
12. Wong GKC, Kwan MCL, Ng RYT, Yu SCH, Poon WS. Flow diverters for treatment of intracranial aneurysms : Current status and ongoing clinical trials q. **J Clin Neurosci**. 2011;18(6):737-740. doi:10.1016/j.jocn.2010.10.011
13. Brinjikji W, Zhu Y-Q, Lanzino G, et al. Risk Factors for Growth of Intracranial Aneurysms: A Systematic Review and Meta-Analysis. **AJNR Am J Neuroradiol**. 2016;37(4):615-620. doi:10.3174/ajnr.A4575
14. Arrese I, Sarabia R, Pintado R, Delgado-Rodriguez M. Flow-Diverter Devices for Intracranial Aneurysms: Systematic Review and Meta-analysis. **Neurosurgery**. 2013;73(2):193-200. doi:10.1227/01.neu.0000430297.17961.f1
15. Jai J, Shankar S, Vandorpe R, Pickett G, Maloney W. ORIGINAL RESEARCH SILK flow diverter for treatment of intracranial aneurysms : initial experience and cost analysis. 2013;1-5. doi:10.1136/**neurintsurg-2012-010590**
16. Briganti F, Leone G, Cirillo L, Divitiis O De, Solari D, Cappabianca P. Postprocedural, midterm, and long-term results of cerebral aneurysms treated with flow-diverter devices: 7-year experience at a single center. 2017;42(June):1-8. doi:10.3171/2017.3.**FOCUS**1732.

Disclosures

The authors report no conflict of interest concerning the materials or methods used in this study or the findings specified in this paper.

Author Contributions

Conception and design: Saal-Zapata. Drafting the article: Saal-Zapata. Critically revising the article: Saal-Zapata. Reviewed submitted version of manuscript: Saal-Zapata. Approved the final version of the manuscript on behalf of all authors: Saal-Zapata.

Correspondence

Giancarlo Saal Zapata. Department of Neurosurgery. Guillermo Almenara National Hospital. 800 Grau Avenue. La Victoria. Lima 13, Perú. E-mail: gian_carlo1987@hotmail.com