

CURATIVE EMBOLIZATION OF DURAL ARTERIOVENOUS FISTULA USING ONYX. CASE REPORT

Embolización curativa de fístula arteriovenosa dural usando Onyx. Reporte de caso

GIANCARLO SAAL-ZAPATA ^{1a}, WALTER DURAND C. ^{1a}, RODOLFO RODRIGUEZ V. ^{1a}

¹Department of Neurosurgery, Section of Neuroradiology, Guillermo Almenara Irigoyen National Hospital, Lima, Perú.
^aNeurosurgeon

ABSTRACT

Introduction: Dural arteriovenous fistulas (DAVF) are vascular lesions that require a high suspicious index for its diagnosis, because of their wide variety of clinical manifestations, moreover, invasive procedures such as digital subtraction angiogram (DSA) is the gold standard and is required for its diagnostic confirmation.

Clinical presentation: We report the case of a previously healthy 44-year-old young woman coming from the highlands of Peru, with the diagnosis of spontaneous intracranial hemorrhage, not treated at her local hospital. She was transferred to the capital city for complementary studies and possible treatment. DSA revealed a dural arteriovenous fistula, with feeder from the middle meningeal artery and venous cortical reflux, being catalogued as a Cognard grade IV/Borden III DAVF, we decided to perform an embolization of the fistulous communication with the non-adherent liquid embolic agent Onyx, with good clinical evolution. Immediate post embolization DSA and 6-month follow-up control DSA showed total absence of the fistula, being the patient catalogued as cured.

Conclusion: Initial diagnostic suspect, digital subtraction angiogram confirmation, an accurate study of the anatomy and the exact location of the fistulous communication are factors that favor the cure in these patients. The treatment in a specialized center that counts with the adequate infrastructure and with trained staff is vital to achieve cure

Keywords: *Fistula, Meningeal Arteries, Intracranial Hemorrhages, Angiography Digital Subtraction. (source: MeSH NLM)*

RESUMEN

Introducción: Las fistulas arteriovenosas durales son lesiones vasculares que requieren alto índice de sospecha para su diagnóstico, ya que se presentan clínicamente de diversas formas, además se requiere de procedimientos invasivos como la angiografía por sustracción digital para su confirmación diagnóstica.

Presentación clínica: Reportamos el caso de una mujer previamente sana de 44 años procedente de la sierra con diagnóstico de un hematoma intracerebral espontáneo, no tratada en su lugar de origen. Es trasladada a la capital para estudio y posible tratamiento. Se diagnostica una fistula arteriovenosa dural con aferente de la arteria menígea media y ectasia venosa siendo catalogada como una fistula Cognard grado IV. Se realiza angiografía diagnóstica y posteriormente embolización del agujero fistuloso con sustancia embolizante Onyx, evolucionando favorablemente. En la angiografía post embolización inmediata y de control a los 6 meses hay ausencia total de fistula, catalogándola como paciente curada.

Conclusión: La sospecha diagnóstica inicial, la confirmación por angiografía cerebral, un adecuado estudio de la anatomía y la localización exacta del agujero fistuloso son factores que favorecen la curación de estos pacientes. El tratamiento en un centro especializado que cuente con la infraestructura adecuada y con personal entrenado es vital para lograrlo.

Palabras Clave: *Fistula, Arterias menígeas, Hemorragia Intracraneal, Angiografía de Substracción Digital. (fuente: DeCS Bireme)*

Peru J Neurosurg 2019, 1 (3): 59-64

Dural arteriovenous fistulas are anastomosis between dural arteries and a venous sinus or its tributaries. Its incidence is 0.17/100,000 persons, they account for the 10%-15% of vascular malformations and the rupture rate is 1.5% per year according to the literature ¹.

At present, the etiology of this lesions are considered either congenital or acquired, being the dural venous sinus thrombosis theory (due to trauma, infection, coagulopathy) the most accepted one, this triggers the release of angiogenic factors like VEGF (vascular endothelial growth factor) and

Submitted: January 06, 2019

Accepted: June 12, 2019

HOW TO CITE THIS ARTICLE: Saal-Zapata G, Durand W, Rodríguez R. Curative embolization of dural arteriovenous fistula using Onyx. Case report. *Peru J Neurosurg* 2019; 1(3): 59-64

HIF (hypoxia induced factor) which creates a microenvironment for proliferation and thickening of dural arteries, allowing anastomosis with dural sinus or its tributaries.^{1,2,3,4}

Clinical presentation depends on location of the lesion, being the most severe bleeding, and when it occurs, it considered a fistula with aggressive clinical presentation, triggering an intracranial bleeding in most of the cases.⁵

Once the diagnosis is done, multiple treatment options exist conservative management, manual occlusion, surgery, endovascular treatment, radiosurgery or the combination of them.^{6,7,8} This will depend on the complexity of the case, nevertheless, nowadays endovascular therapy is the first line treatment.⁶

We report the case of a young patient, whose initial clinical presentation was intracranial hemorrhage due to a Cognard IV/Borden III ruptured DAVF,^{9,10} not treated in its local hospital, and transferred to our hospital, a specialized center in the management of neuro vascular pathology. The patient was treated with endovascular therapy

CASE REPORT

History and clinical examination: Previously healthy 44year-old woman who came from Huancayo (highlands of Peru), suddenly presents headache, nausea, vomiting and loss of consciousness. She was taken to a regional hospital where a brain CT scan was performed showing a left frontal basal intracranial hemorrhage, she is admitted and treated in a conservative manner. Three weeks after the ictus is referred to our institution for complementary studies and possible treatment. Patient is admitted in the emergency department, she is awake, GCS: 15 points, without motor weakness, pupils are reactive, no nuchal rigidity. A CT scan is also performed and reveals the reabsorption of the hematoma, an angio-CT scan is also performed revealing a possible ruptured arteriovenous fistula versus an

arteriovenous malformation (**Fig 1**). Four vessel digital subtraction angiography is performed showing a dural arteriovenous fistula with left middle meningeal artery feeder which is thickened, there is also cortical retrograde venous drainage to the anterior third of sagittal sinus and venous ectasia with a venous aneurysm, being catalogued as Cognard type IV/Borden type III DAVF (**Fig 2**).

Treatment: We planned embolization of the fistula with the aim to obliterate the fistulous communication: the procedure was performed in the Neuroradiology suite of the Hospital Nacional Guillermo Almenara, the biplanar angiograph Phillips ALLURA 3D was used.

We started the procedure with puncture of the femoral artery by Seldinger's technique, then a 6F sheath was introduced, afterward a Chaperon 6F catheter (Microvention), Headway Duo microcatheter (Microvention) and Hybrid 007D microwire (BALT) were employed for the procedure. We first performed an angiogram of both internal carotid arteries and vertebral arteries to rule out anomalies. Afterwards we navigated through the left external carotid and middle meningeal artery, we performed an ultra-selective angiogram to confirm we were in the right position of the fistulous communication. Once the position was confirmed, DMSO and 2.25 ml of embolic agent Onyx (Medtronic) were injected, been aware of reflux to the parent artery.

After Onyx injection we appreciate absence of the fistula with poor reflux of the embolic agent to the parent artery. At the end of the procedure another control angiogram was performed showing total obliteration of the DAVF. Total time of the procedure was thirty minutes and there were no complications (**Fig 3**).

Clinical evolution: After the procedure, patient's clinical course was stable, without neurological impairment, brain CT scan revealed no bleeding, the frontal basal hematoma was almost reabsorbed (**Fig 4**). She was discharged two

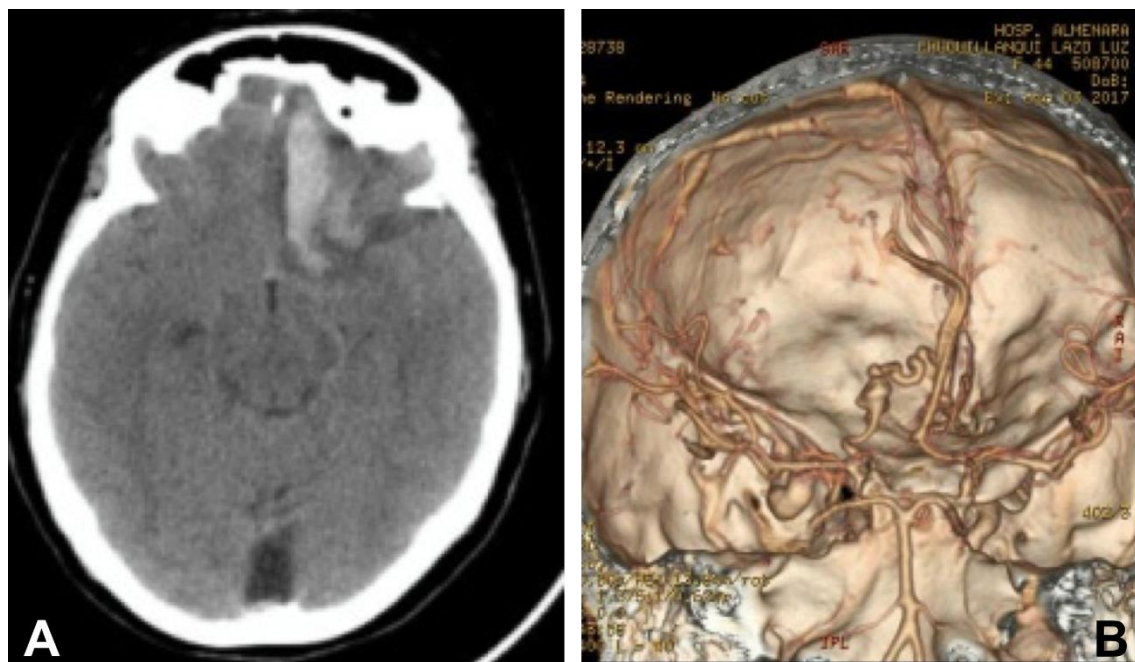


Fig 1: (A) Pre-operative CT scan reveals left frontal hematoma due to ruptured dural arteriovenous fistula. **(B)** Brain angio-CT scan reveals fistula with venous ectasia

days after the procedure without interurrences. Six months follow up DSA showed total obliteration of the fistula.

DISCUSSION

Access to specialized medical attention in provinces is poor, so that patients with neuro vascular pathology must be transferred to the capital city for diagnosis and treatment,

many times lately as shown in this case (three weeks later) ¹¹ Dural arteriovenous fistulas are rare vascular lesions, diagnostic suspicious must be high due to their rareness and their multiple clinical presentations: in case of non-ruptured ones, delayed neurologic deficit, headache, tinnitus, among others. These symptoms will depend on the location of the fistula. On the other hand, in most of the cases the ruptured one debut with intracranial hemorrhage and less frequently

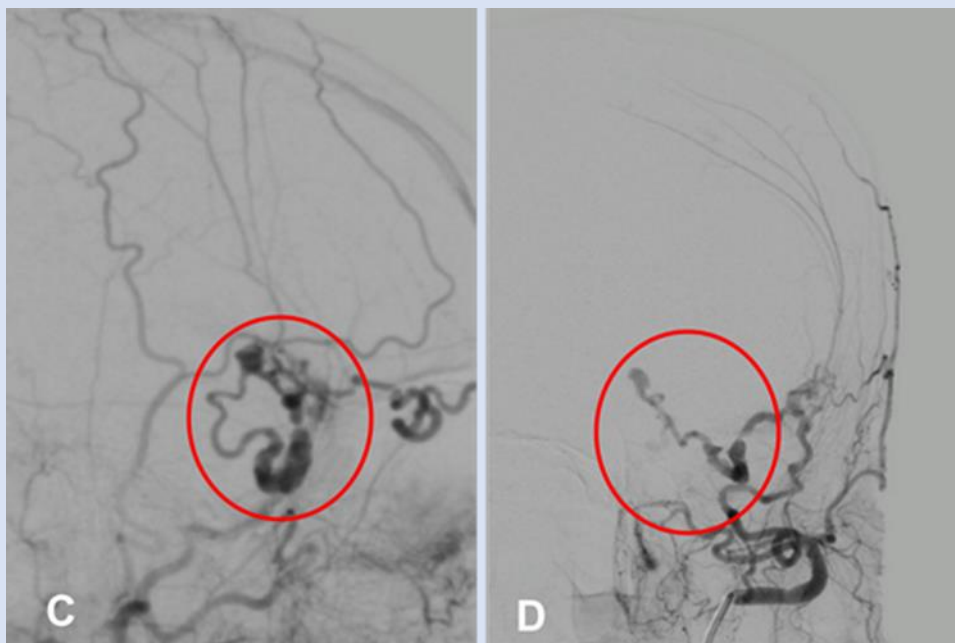


Fig 2: (C) External carotid angiogram in lateral view, reveals dural arteriovenous fistula with left middle meningeal artery feeder. (D) External carotid angiogram in anteroposterior view, reveals dural arteriovenous fistula with ectasia and venous aneurysm, draining to the longitudinal superior sinus.

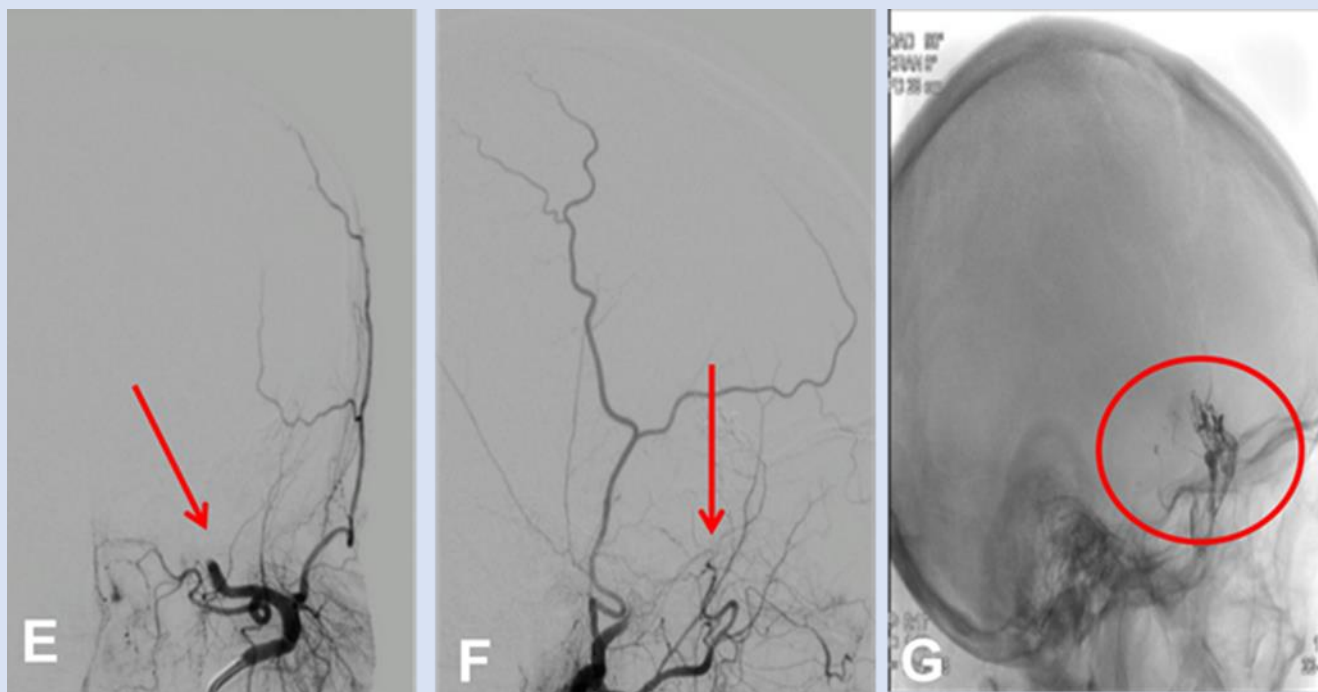


Fig 3. (E y F) Immediate angiographic injection in anteroposterior and lateral views reveals absence of fistula with Onyx embolization and obliteration of the fistulous communication. (G) Lateral view reveals Onyx cast.

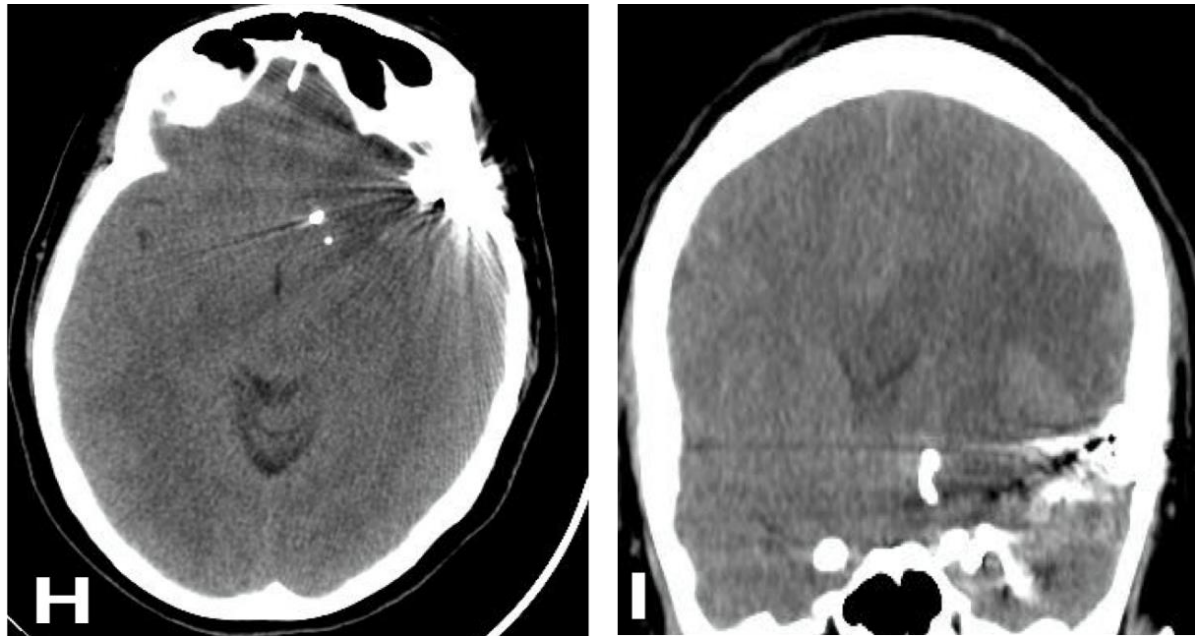


Fig. 4. (H, I) Control CT scan of embolized fistula with Onyx, no evidence of bleeding and left frontal hematoma almost reabsorbed

subdural hematoma. Some radiologic exams can help, such as brain CT scan, magnetic resonance and doppler, nevertheless, brain digital subtraction angiography (DSA) remains the gold standard to confirm the diagnosis, classify according to Cognard / Borden systems of classification and plan the correct treatment.¹²

Two classification systems exist for the study of dural arteriovenous fistulas: Borden and Cognard, both of them aim to grade the lesions, identify what type of fistula requires treatment and the prognostic regards to bleeding. Clinical evolution will depend on the venous compromise of the fistula: the presence of cortical venous reflux is a predisposing factor for its rupture, presenting in high grade fistulas in most of the cases. Conservative management is recommended for Cognard I and II a/Borden I lesions because of absence of venous ectasia and low risk of bleeding.

Nowadays endovascular treatment is of choice, with the employment of non-adherent embolic agents such as Onyx, the occlusion of the fistulous communication is achieved in a safe manner, this technique allows an adequate navigation through the cerebral arteries, but we have to be aware of reflux in the parent artery while injecting it. We can opt for trans-arterial or transvenous approach, depending on the fistula characteristics. Reported cure rates with the use of Onyx range from 60% - 100.^{13,14} Additionally N-butyl-2 cyanoacrylate combined with lipiodol can be used in cases Onyx is not available.¹⁵

In this case, we found a fistula with a feeder from the left middle meningeal artery with leptomeningeal venous drainage and cortical retrograde venous ectasia, so we classified it as a Cognard type IV/Borden III fistula. With this in mind, we decided to perform endovascular treatment with the aim to identify and occlude the fistulous communication: this is the goal of treatment and always must be done, otherwise cure won't be achieved. We decided to use Onyx, a non-adherent liquid embolic agent compound of ethylene-vinyl-alcohol copolymer and its

solvent DMSO, achieving the occlusion of the lesion successfully. Six-month follow-up shows absence of the lesion.

CONCLUSION

At present, endovascular therapy is the treatment of choice in the management of dural arteriovenous fistulas. The use of embolic agents like Onyx has allowed the cure in a great percentage of patients.

REFERENCES

- Ghobrial GM, Marchan E, Nair AK, Dumont AS, Tjoumakaris SI, Gonzalez LF, et al. Dural arteriovenous fistulas: A review of the literature and a presentation of a single institution's experience. **World Neurosurg** [Internet]. 2013;80(1-2):94-102. Available from: <http://dx.doi.org/10.1016/j.wneu.2012.01.053>
- Baltsavias G, Parthasarathi V, Aydin E, Al Schameri RA, Roth P, Valavanis A. Cranial dural arteriovenous shunts. Part 1. Anatomy and embryology of the bridging and emissary veins. **Neurosurg Rev.** 2015;38(2):253-64.
- Baltsavias G, Kumar R, Avinash KM, Valavanis A. Cranial dural arteriovenous shunts. Part 2. The shunts of the bridging veins and leptomeningeal venous drainage. **Neurosurg Rev.** 2015;38(2):265-72.
- Tsai LK, Liu HM, Jeng JS. Diagnosis and management of intracranial dural arteriovenous fistulas. **Expert Rev Neurother.** 2016;16(3):307-18.
- Gross BA, Du R. The Natural History of Cerebral Dural. Vol. 71, **Neurosurgery.** 2012. p. 594-603.
- Hacein-Bey L, Konostas AA, Pile-Spellman J. Natural history, current concepts, classification, factors impacting endovascular therapy, and pathophysiology of cerebral and spinal dural arteriovenous fistulas. **Clin Neurol Neurosurg** [Internet]. 2014;121:64-75. Available from: <http://dx.doi.org/10.1016/j.clineuro.2014.01.018>
- Gross BA, Ropper AE, Popp AJ, Du R. Stereotactic radiosurgery for cerebral dural arteriovenous fistulas. **Neurosurg Focus** [Internet]. 2012;32(5):E18. Available from: <http://thejns.org/doi/10.3171/2012.1.FOCUS11354>
- Kawaguchi S, Sakaki T. Surgical treatment of intracranial

- dural arteriovenous fistulas. **Brain and Nerve.** **2008;60(8):897–906.**
9. Cognard C, Gobin YP, Pierot L, Bailly AL, Houdart E, Casasco A, et al. Cerebral dural arteriovenous fistulas: clinical and angiographic correlation with a revised classification of venous drainage. **Radiology [Internet].** **1995;194(3):671–80.** Available from: <http://www.ncbi.nlm.nih.gov/pubmed/7862961>
 10. Al-Mahfoudh R, Kirolos R, Mitchell P, Lee M, Nahser H, Javadpour M. Surgical disconnection of the cortical venous reflux for high-grade intracranial dural arteriovenous fistulas. **World Neurosurg [Internet].** **2015;83(4):652–6.** Available from: <http://dx.doi.org/10.1016/j.wneu.2014.12.025>
 11. Choque-Velasquez J, Colasanti R, Baffigo-Torre V, Societa-Carbajo LE, Olivari-Heredia J, Falcon-Lizaraso Y, et al. Developing the First Highly Specialized Neurosurgical Center of Excellence in Trujillo, Peru: Work in Progress—Results of the First Four Months. **World Neurosurg [Internet].** **2017;102:334–9.** Available from: <http://dx.doi.org/10.1016/j.wneu.2017.01.063>
 12. Lenthall R. Intracranial dural arteriovenous fistulas. **Interv Neuroradiol.** **2014;151–68.**
 13. Sadeh-Gonike U, Magand N, Armoiry X, Riva R, Labeyrie PE, Lamy B, et al. Transarterial Onyx Embolization of Intracranial Dural Fistulas: A Prospective Cohort, Systematic review, and Meta-Analysis. **Neurosurgery [Internet].** **2017;0(0):1–10.** Available from: <http://academic.oup.com/neurosurgery/advance-article/doi/10.1093/neuros/nyx309/3869481>
 14. Pierot L, Cognard C, Herbreteau D, Fransen H, Van Rooij WJ, Boccardi E, et al. Endovascular treatment of brain arteriovenous malformations using a liquid embolic agent: Results of a prospective, multicentre study (BRAVO). **Eur Radiol.** **2013;23(10):2838–45.**
 15. Rabinov JD, Yoo AJ, Ogilvy CS, Carter BS, Hirsch JA. ONYX versus n-BCA for embolization of cranial dural

arteriovenous fistulas. **J Neurointerv Surg.** **2013;5 (4):306–10.**

Disclosures

The authors report no conflict of interest concerning the materials or methods used in this study or the findings specified in this paper.

Author Contributions

Conception and design: All the authors. *Drafting the article:* Saal-Zapata. *Critically revising the article:* Rodriguez R. *Reviewed submitted version of manuscript:* Saal-Zapata. *Approved the final version of the manuscript on behalf of all authors:* Saal-Zapata.

Correspondence

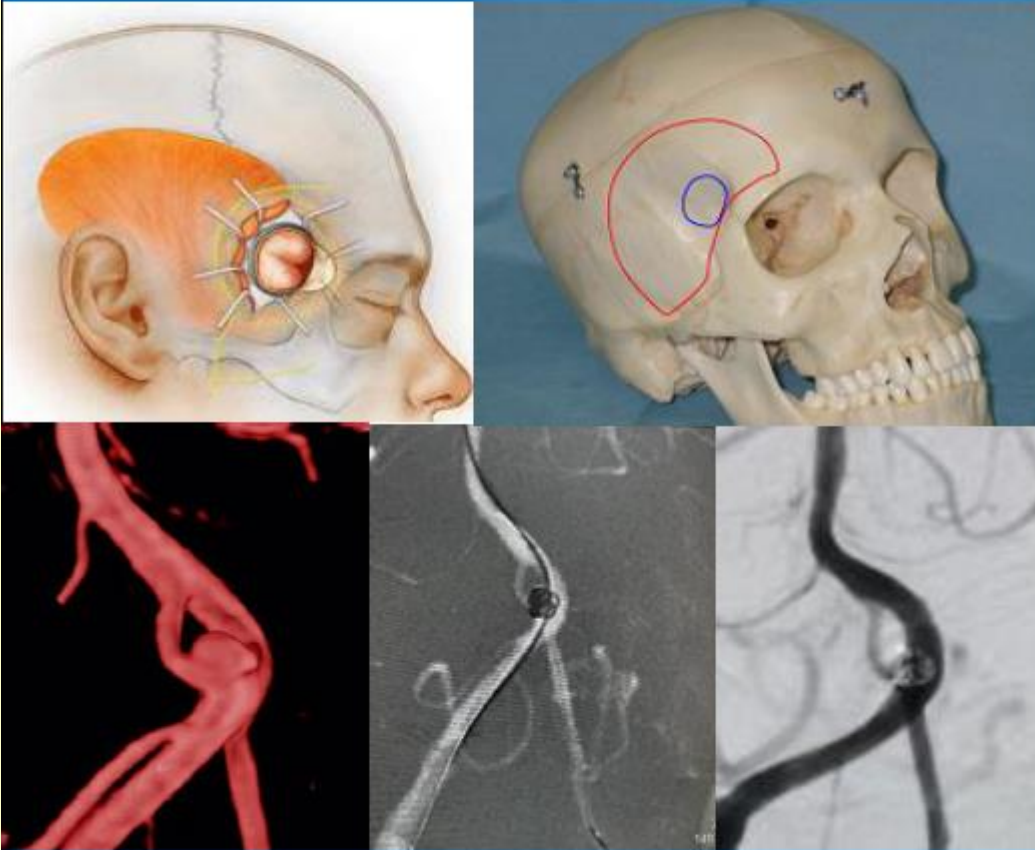
Giancarlo Saal Zapata. Department of Neurosurgery. Guillermo Almenara National Hospital. 800 Grau Avenue. La Victoria. Lima 13, Perú. E-mail: gian_carlo1987@hotmail.com

PREVIOUS ISSUE

PJNS PERUVIAN JOURNAL OF
NEUROSURGERY

Vol 1 | Issue 2 | Apr-Jun 2019

INTRACRANIAL ANEURYSMS



Minimally Invasive Surgery and Endovascular Treatment