

SEVERE INTRACRANIAL HYPERTENSION TREATED WITH 7.5% HYPERTONIC SOLUTION IN A SUBARACHNOID HEMORRHAGE CASE BY RUPTURE OF ANEURYSM

Manejo de hipertensión endocraneal severa con solución hipertónica al 7,5% en un caso de hemorragia subaracnoidea por ruptura de aneurisma

OSCAR SALDARRIAGA R.^{1a}, ELAR CARI C.^{1b}, GRACIELA NUÑEZ Z.^{1c}

¹Intensive Care Unit, Department of Neurosurgery, Guillermo Almenara Irigoyen National Hospital, Lima, Perú,

^a Neurointensivist, ^bNeurosurgeon, ^cNurse of Neurosurgical ICU

ABSTRAC

Introduction: All patients with subarachnoid hemorrhage (SAH) admitted to our department are managed in intensive care unit; in the last years there has been a tendency to treat aneurysms in early stage by craniotomy or embolization, however the clinical evolution of patients is difficult in some cases because the neurosurgical critical care staff face with cerebral edema, intracranial hypertension, cerebral hypoperfusion and cerebral vasospasm among others but this early treatment has reduce the rate of rebleeding.

Clinical case: We report the case of a 52-year-old woman with a diagnosis of subarachnoid hemorrhage who was monitored with an intracranial pressure (ICP) sensor and transcranial Doppler (TCD) and who received treatment with hypertonic solution at 7.5% presenting a good evolution.

Conclusion: This case show us how the clinical monitoring, ICP, TCD as well as treatment with hypertonic saline solutions are good complement to take correct decisions in shortest time, because "time is brain".

Keywords: Subarachnoid Hemorrhage, Intracranial Pressure, Hypertonic Solutions. (source: MeSH NLM)

RESUMEN

Introducción: Todos los pacientes con hemorragia subaracnoidea (HSA) que ingresan a nuestro departamento son manejados en la unidad de cuidados intensivos; en los últimos años ha habido una tendencia al manejo temprano de asegurar el aneurisma ya sea por craneotomía y/o embolización sin embargo la evolución clínica en muchas oportunidades es de difícil manejo, justamente porque el manejo se hace en forma temprana; el staff de cuidados críticos neuroquirúrgicos se enfrenta al edema cerebral, hipertensión endocraneal, hipoperfusión cerebral y vasoespasmo cerebral entre otras pero se ha logrado reducir al máximo la tasa de resangrado.

Caso clínico: Reportamos el caso de una mujer de 52 años con diagnóstico de hemorragia subaracnoidea que fue monitoreada con sensor de presión intracraneal (PIC) y Doppler transcraneal (DTC) y que recibió tratamiento con solución hipertónica al 7.5% presentando una buena evolución.

Conclusión: El presente caso muestra como el monitoreo de la clínica, Doppler transcraneal y presión intracraneal, así como el tratamiento con solución hipertónica se complementan para tomar decisiones correctas en el menor tiempo posible, pues se cumple la frase "time is brain".

Palabras clave: Hemorragia Subaracnoidea, Presión Intracraneal, Soluciones hipertónicas. (fuente: DeCS Bireme)

Peru J Neurosurg 2019, 1 (2): 37-41

CLINICAL CASE

The monitoring of intracranial pressure (ICP) has become one of the most important pillars of multimodal monitoring which is complemented by the different monitoring tools of the neurocritical care units. The present case is presented for the knowledge of the strategies used for the control of brain injury and thereby improve the recovery of the patient as much as possible.

Submitted : February 28, 2018

Accepted : December 10, 2018

HOW TO CITE THIS ARTICLE: Saldarriaga O, Cari E, Nuñez G. Severe intracranial hypertension treated with 7.5% hypertonic solution in a subarachnoid hemorrhage case by rupture of aneurysm. *Peru J Neurosurg* 2019; 1(2): 37-41

History and examination: A 52-year-old woman with a history of high blood pressure in irregular treatment, who on 14/09/12 at 00:30 am suddenly presented with severe headache, nausea and vomiting followed by loss of consciousness. She was brought to Emergency where a blood pressure: 150/80 was found, GCS 12 pts., neck rigidity ++/+++ , no motor deficit, mobilized the limbs, ventilated

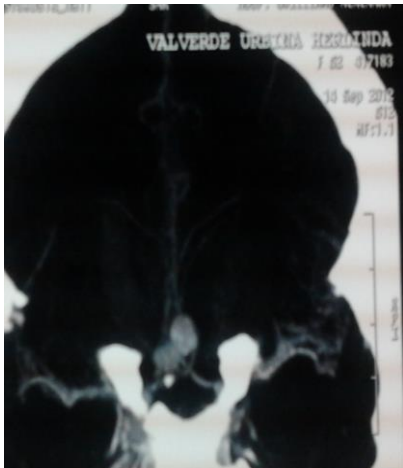


Fig 1. Cerebral Angio-CT showing a bilobed anterior communicating artery aneurysm.

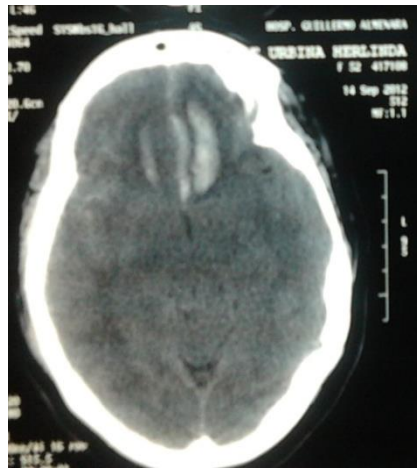


Fig 2. Brain CT at the beginning showing area of frontal intracerebral hematoma with minimal cerebral edema.

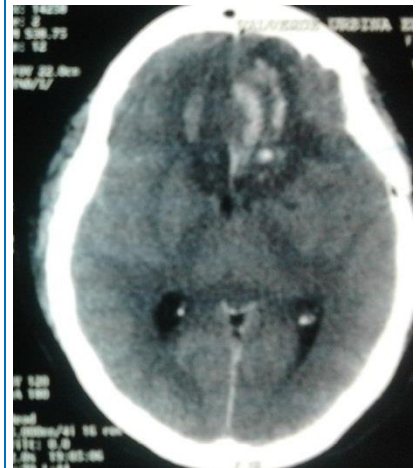

Fig 3. Brain CT post neurological deterioration and with cerebral flow velocities with high resistance pattern.

spontaneously. Cerebral CT: Fisher IV subarachnoid hemorrhage (SAH) with blood in basal cisterns and interhemispheric fissure with fronto-basal hematoma, bilateral ventro-medial, angio-CT: Ruptured bilobed aneurysm of anterior right communicating artery. **(Fig 1)**

Treatment: On 09/15/12, a craniotomy with aneurysm clipping was performed. Patient went to neurosurgical ICU for monitoring and management.

In Intensive Care Unit, a CT scan was taken that showed a hematoma similar to the pre-surgical one **(Fig 2)**. Patient was hydrated with physiological serum and electrolytes at 100 cc/h, she received 150cc of 3% hypertonic saline solution (HSS) every 4 hours, nimodipine 60 mg every 4 hours, antibiotic prophylactic and midazolam adjustable fentanyl low dose, mechanical ventilation and glycemic

control. Stable vital functions (150/80mmHg, HR: 80 bpm, RR: 16 breaths per minute, adequate diuresis, neutral water balance).

Evolution: The initial neurological evolution was good, wakes up to the call, obeys orders, no motor or pupillary deficit, remains in mechanical ventilation with Ramsay 3. Supportive therapy was maintained. In the afternoon we proceed to place in T-tube, tolerating the test, saturating 98% with 50% If O₂ with T-tube.

At **18 o'clock**, the patient presented polypnea and bad ventilatory pattern, so the team proceeded to reconnect her to a mechanical ventilator. At the neurological examination, the patient was soporous, with right anisocoria and left hemiplegia (it was striking because craniotomy was performed on the left side). Transcranial Doppler (TCD) was performed, finding the flow in left MCA with MV: 32 cc/s

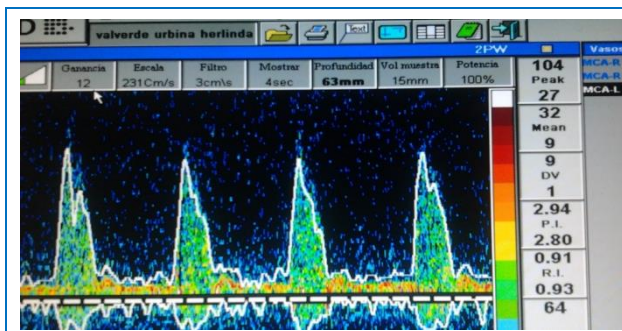


Fig 4. Left MCA MV: 32 cc/s PI: 2,94 (MCA: Medial Cerebral Artery, MV: Medial Velocity, PI: Pulsatility Index)

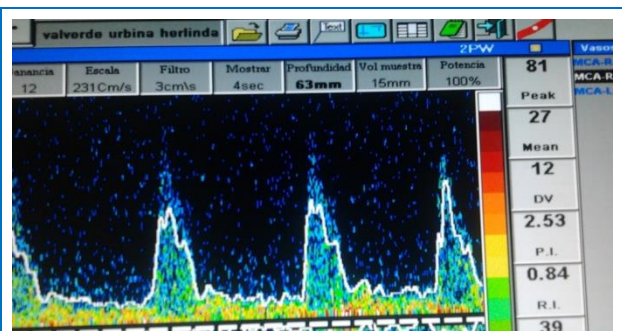


Fig 5. Right MCA MV: 27 CC/S PI: 2.53 (MCA: Medial Cerebral Artery, MV: Medial Velocity, PI: Pulsatility Index)

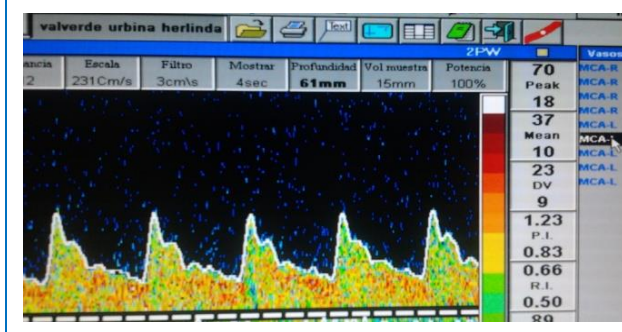


Fig 6. Left MCA MV: 37 CC/S PI: 1,23 (MCA: Medial Cerebral Artery, MV: Medial Velocity, PI: Pulsatility Index)

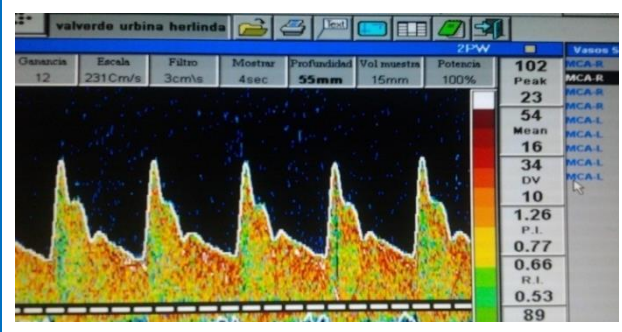


Fig 7. Right MCA MV: 54 CC/S PI: 1.26 (MCA: Medial Cerebral Artery, MV: Medial Velocity, PI: Pulsatility Index)

and an PI: 2.94, and in right MCA the MV: 27 cc/s and PI: 2.53 (Fig 4 and 5), which evidenced a marked decrease in diastolic velocity and marked increase in the pulsatility index (PI). The cerebral perfusion pressure (CPP: DV x MAP/MV +14) by Doppler in right MCA was 39 (9x 90/32 + 14 = 39), and in left MCA it was 54 (12 x 90/27 + 14 = 54) showed that the right hemisphere is the most compromised which correlates with the left motor deficit. A bolus of 7.5% HSS 150cc stat was administered and a tomography was performed in the event of suspicion of rebleeding, hydrocephalus or increased cerebral edema.

The CT scan showed greater cerebral edema (Fig 3), so we proceeded to the placement of a ICP catheter, finding a pressure of 38mmHg before which we opted for medical management of IC hypertension (osmotherapy, controlled hyperventilation) with 150cc of 7.5% hypertonic saline solution PRN to ICP greater than 20 and treatment was also started with noradrenaline in infusion to bring the MAP 90 to 110mmHg, sedation and analgesia is reinstated.

At 21h, the control TCD showed the following values: In left MCA, MV: 37 cc/s and PI: 1.23, while the right MCA, VM: 54cc/s and an PI: 1.26. The cerebral perfusion pressure by Doppler in right MCA was 71 (23x 92/37 + 14 = 71) and in left MCA it was 72 (34x92 / 54 + 14 = 72), which concluded that cerebral perfusion improved. (Fig 6 and 7)

On 09/16/12. At 9am, patient remains sedated in mechanical ventilation, hemodynamically stable, isochoric pupils 2mm. Punctiform pupils and continued like this throughout the day. Received 7 boluses of 150cc of 7.5% HSS (1st day with PIC sensor)

09/17/12. The patient is maintained with sedation and analgesia, with adequate MAP, without requiring much ventilatory support, feverish course so antibiotic coverage is changed and culture is taken endotracheal aspirate, serum Na + 158 so it is administered interspersed hypertonic saline solution and mannitol, sedation and analgesia, vasopressors, antipyretics are still in place and blood gas analyses (BGA) every 8h as well as glucose. Received 3 boluses of 7.5% HSS and 01 bolus of 200cc of 20% mannitol (2nd day with ICP monitoring)

09/18/12. He received 01 bolus of 7.5% HSS and 03 boluses of 150cc of 20% mannitol as he presented hypernatremia. (3rd day with ICP sensor). Transcranial Doppler showed right MCA velocity: 145 and left MCA: 95, so, the right Lindegaard index was: 4.8 and the left was 3.6 (values > 3, it means vasospasm), so it was maintained with hypervolemic therapy. (Fig 8 and 9)

09/19/12. He received 03 boluses of HSS at 7.5% and 04 bolus of 100cc 20% mannitol. (4th day with ICP sensor)

09/20/12. Fever reaches 39.50°C despite antipyretic (paracetamol on schedule), Diclofenac infusion was started with which temperature fell in two hours and remained afebrile the rest of the day. He received 01 boluses of HSS at 7.5% and 02 bolus of 200cc of 20% mannitol. (5th day with ICP sensor)

09/21/12. Patient is maintained with sedation and analgesia, ICP <20 mmHg with 7.5% SSH, result of culture of aspirate showed E. coli ESBL and P. aeruginosa sensitive to Imipenen, so antibiotic coverage was changed by diagnosis of intrahospital pneumonia (IHN). He did not receive hypertonic or mannitol. (6th day with ICP sensor)

09/22/12. Patient with IHN, opens the eyes, but does not connect with the environment, does not locate the pain (noxa), persists feverish, osmotherapy is reduced due to better ICP control. The sensor is removed and 100cc of 7.5% HSS every 4h is indicated. He received 01 bolus of HSS at 7.5% and 02 boluses of 200cc of 20% mannitol. (7th day with ICP sensor)

09/24/12. Patient ventilates with T-tube, ocular opening to the pain, but does not localize, quadriplegia marked, photo-reactive isochoric pupils, sedation has been withdrawn 12 hours before the evaluation, receives treatment for IHN, fever has descended, still receives descending vasopressors. Was changed from HSS from 7.5 to 3%, 150cc every 4 h

9/27/12. Patient spontaneously ventilates with T-tube, obeys simple orders, quadriplegia with greater deficit on

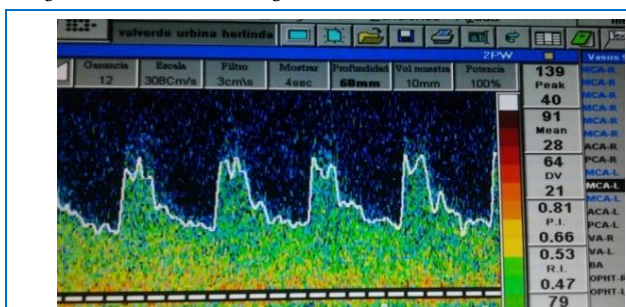


Fig 8. Left MCA MV: 95 CC/S PI: 1,23 (MCA: Medial Cerebral Artery, MV: Medial Velocity, PI: Pulsatility Index)

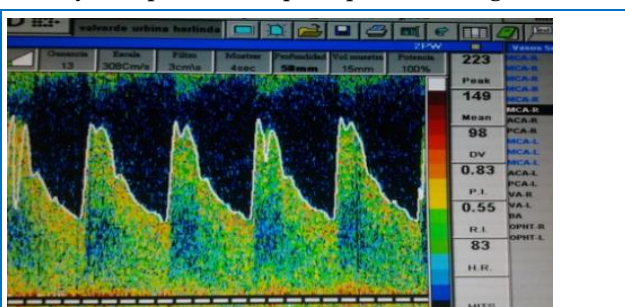


Fig 9. Right MCA MV: 145 CC/S PI: 0,83 (MCA: Medial Cerebral Artery, MV: Medial Velocity, PI: Pulsatility Index)

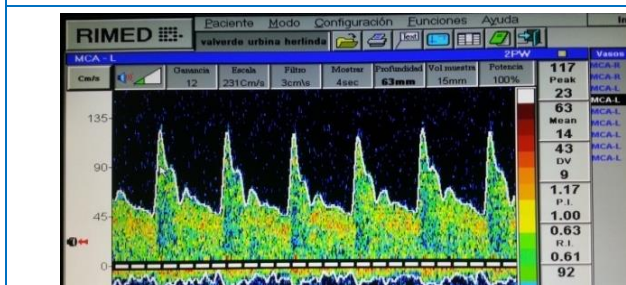


Fig 10. Left MCA MV: 63 CC/S PI: 1,17 (MCA: Medial Cerebral Artery, MV: Medial Velocity, PI: Pulsatility Index)

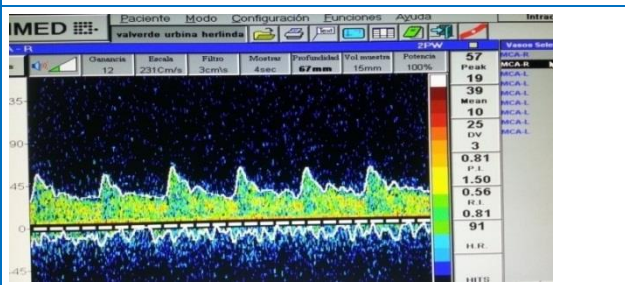


Fig 11. Right MCA MV: 39 CC/S PI: 0,81 (MCA: Medial Cerebral Artery, MV: Medial Velocity, PI: Pulsatility Index)

the left side, reactive 3mm isochoric pupils, Glasgow Coma Scale reaches 10 (O3, V1, M6), afebrile with little secretion due to orotracheal tube OTT. (Fig 10 and 11)

09/30/12. Patient tolerated extubating, awake obeys simple orders with moderate left hemiparesis, Glasgow 12 (O4, V2, M6), even with dopamine at 16cc / h (16ug / kg / min).

09/04/12. We achieved "weaning" of dopamine, wake up call, obey orders, Glasgow 13, with mild left hemiparesis. Without fever, go to Intermediate Care Unit. (Fig 12 and 13)

10/29/12. Patient is seen in neurosurgery clinic, in Glasgow 15 without motor deficit, with slight alteration of memory. Ranking Scale 2. She was transferred to physical medicine to continue with a rehabilitation program.

DISCUSSION

Over the last 25 years, transcranial Doppler (TCD) has managed to take its place in the diagnostic arsenal for the vascular neurologist and the neurointensivist, becoming a true "brain stethoscope" and an extension of neurological exploration. Being the only non-invasive diagnostic method capable of evaluating cerebral blood flow in real time, it adds precious physiological information to the structural image of the brain.¹

TCD was introduced in clinical practice in 1982² and from the beginning several groups of researchers focused their attention on its possibilities as an auxiliary technique in the study of acute cerebrovascular pathology³ establishing its diagnostic yield in comparison with angiographic studies.⁴

Aaslid² used for the first time an ultrasound transmitter with a frequency of 2 MHz, demonstrating that at this frequency (the lowest of those used in medicine) ultrasound was able to pass through the skull and accurately measure the speed and direction of the cerebral blood flow in the cerebral vessels of the polygon of Willis and its arterial branches that constitute it.

The fundamental concept to highlight is that the TCD, like all Doppler techniques, measures speeds; in this case it measures cerebral blood flow velocity (CBFV), which is different from cerebral blood flow (CBF), a point to be taken into account when interpreting high speeds that do not always correlate with high flows.

In this case of subarachnoid hemorrhage (SAH), we wanted to demonstrate the usefulness of the TCD, which can not only serve us for the monitoring of vasospasm related to

SAH but also allows us to indirectly identify the degree of intracranial hypertension and cerebral perfusion in a dynamic way.

It can be seen, as when the patient was with clinical deterioration (anisocoria and Glasgow deterioration), the Doppler showed us very high pulsatility indexes with Doppler waves with systolic peaks and marked decrease in diastole which correlates with increased ICP and above all low cerebral perfusion.⁵

When we apply the non-invasive perfusion pressure formula, calculated from the parameters obtained in the DTC ($Vd \times PAM / VM + 14$),^{6,7} we observe a very low PPC. These conditions of low perfusion are correlated with low contribution or with a very high ICP, in our specific case the suspicion was that the ICP was elevated due to cerebral edema, which correlated with the clinical picture of that moment, probably if we had had a PIC already installed we would have been located in the nadir of A wave, the same ones that have a malignant behavior when the "cerebral compliance" is at the limit as the case of this patient. This was immediately corroborated with the cerebral CT, but the most important thing was that it was acted opportunely when changing the hypertonic saline solution from 3% to a 7.5% given in boluses of 150cc. Only in the face of suspicion, a situation that can be found many times in our daily practice and sometimes without having all the necessary arsenal available, we could act empirically.

Later, when the fiber optic sensor was placed to measure the ICP, the intracranial hypertension was corroborated, however the treatment was already indicated, since we had already placed hypertonic solution long before placing the ICP sensor.

In our hospital, the management of hypertonic solutions we have been doing since 2006, having acquired enough experience to recommend its use, taking care to have a strict control of electrolytes, cardiovascular, respiratory and renal function, which is essential in these patients to avoid hydro-electrolytic and cardiorespiratory disorders.

This case also shows us the importance of having a CT availability 24 hours a day in cases of brain surgery, since post-operated patients need a CT scan within the first 12 hours after surgery, and the time of indication of the CT scan may vary according to the clinical evolution. As expected, our patient presented vasospasm by Doppler on the third day after recovering from the acute diffuse cerebral hypoperfusion, management was done with "triple H" therapy (hypertension and hypervolemia avoiding anemia).

The important thing to emphasize when vasospasm is detected by TCD is that often there is no clinical translation, however, this allows us to quickly start the medical measures of the treatment of vasospasm, including

	Day 1							Day 2				Day 3				Day 4					Day 5				
	1	2	3	4	5	6	7	8	9	10	11	12	13	14	15	16	17	18	19	20	21	22	23	24	25
ICP	36	29	21	23	22	20	25	20	35	26	22	26	24	26	28	25	28	24	22	27	19	23	25	18	20
CPP	60	85	87	84	78	83	72	72	62	80	79	76	66	78	86	109	89	85	91	76	81	87	80	90	88
MAP	96	114	108	107	100	103	97	92	97	106	101	102	90	104	114	134	117	109	113	103	100	110	105	108	108
Manitol											200		150	100	100	100	100		100	100				200	200
HSS	150	150	150	150	150	150	150	150	150	150		150						150			150	150	150		

Table 1. Hours in which hypertonic saline solution was administered were shown, during the rest of the day the ICP remained controlled with adequate cerebral perfusion pressure. (ICP: Intracranial pressure, CPP: Cerebral perfusion pressure, MAP: Mean arterial pressure, HSS: Hypertonic saline solution)

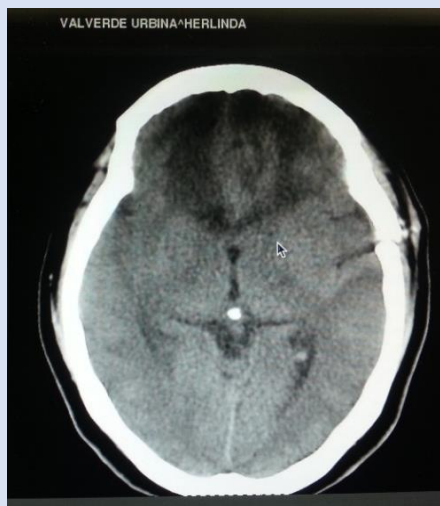


Fig 12. Control CT 10 days after HSA

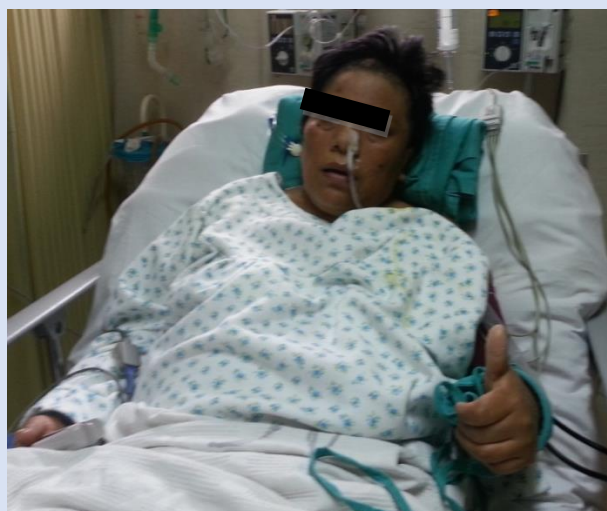

Fig 13. Patient in good clinical condition after leaving the ICU

endovascular treatment (angioplasty or infusion of vasodilators). The concept that the TCD allows the diagnosis of vasospasm before it translates into clinical symptomatology is fundamental, since the clinical symptomatology is a manifestation of DID (delayed ischemic deficit, often a irreversible situation) which allows to prevent the complications of vasospasm.

The TCD therefore, provides an optimal therapeutic window for ischemia. The importance and usefulness of the TCD are related to the possibility of evaluating the CBFV (cerebral blood flow velocity) in a repetitive or continuous way, allowing a dynamic correlation with the clinical evolution, in a non invasive way and next to the bed of the patient, making transfers unnecessary which is often difficult and high risk.⁸

We wanted to show this case because the clinical evolution that is the most important was very good and above all it was the long-term recovery, which shows once again that the phrase "time is brain" is very true, so it is essential act quickly.

CONCLUSION

In conclusion, we can say that the DTC is a useful tool for the hemodynamic monitoring of the brain when there is cerebral injury due to subarachnoid hemorrhage, it allows us to act in time, since it is a non-invasive tool that is done in the patient's bed; its knowledge and use is fundamental in the neurocritical care units and thus gain time in the initial treatment.

REFERENCES

- Alexandrov AV, Molina CA, Grotta JC, et al. Ultrasound enhanced systemic thrombolysis for acute ischemic stroke. *N Engl J Med.* 2004; 351: 2170-8
- Aaslid R, Markwalder TM, Nornes H. Noninvasive transcranial Doppler ultrasound recording of flow velocity in basal cerebral arteries. *J Neurosurg.* 1982; 57: 769-74
- Grolimund P, Seiler RW, Aaslid R, Huber P, Zurbrugg H. Evaluation of cerebrovascular disease by combined extracranial and transcranial doppler sonography. Experience in 1,039 patients. *Stroke.* 1987; 18: 1018-1024
- Razumovsky AY, Gillard JH, Bryan RN, et al. TCD, MRA and MRI in acute cerebral ischemia. *Acta Neurol Scand.* 1999; 99: 65-76. 5,6
- R Lagos, F Murillo Cabezas, L Fernández Cisneros Doppler Transcranial Técnica e Indicaciones. *Archivos de Neurocirugía, Neurología y Neuropsiquiatría* 2007
- MJ Domínguez Rivas, A Sánchez Rodríguez, Parámetros de Doppler transcranial en Pacientes con TEC severo, *Hospital Universitario Puerta del Mar Cádiz,* 2005
- Czosnyka M, Matta BF, Smielewski P, et al: Cerebral Perfusion pressure in head injured patients: a noninvasive assessment using transcranial Doppler ultrasonography. *J Neurosurgery* 88: 802 – 808, 1998
- Corina Puppo, Doppler transcranial en el paciente neurocrítico. *Pac crítico* 2001; 14(1): 49-66.

Disclosures

The authors report no conflict of interest with any commercial distributor of the devices used in this study, methods or the findings specified in this paper.

Author Contributions

Conception and Design: Saldarriaga, Cari, Nuñez. *Drafting the article:* Saldarriaga. *Critically revising the article:* Saldarriaga, Cari. *Reviewed submitted version of manuscript:* Saldarriaga. *Approved the final version of the manuscript on behalf of all authors:* Saldarriaga.

Correspondence

Oscar Saldarriaga Rivera. Intensive Care Unit. Department of Neurosurgery. Guillermo Almenara Hospital. 800 Grau Avenue. La Victoria. Lima 13, Perú. *E-mail:* dac.sal2001@gmail.com

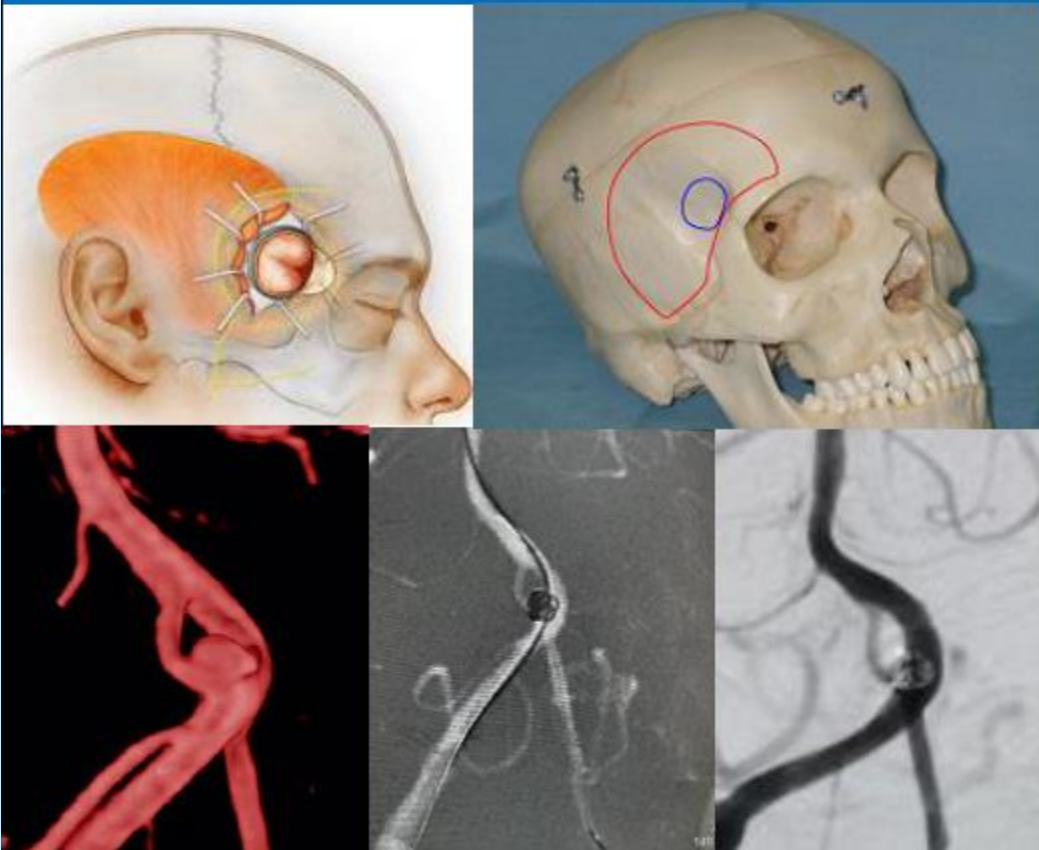
CURRENT ISSUE

PJNS

**PERUVIAN JOURNAL OF
NEUROSURGERY**

Vol 1 | Issue 2 | Apr-Jun 2019

INTRACRANIAL ANEURYSMS



Minimally Invasive Surgery and Endovascular Treatment