

# CURATIVE TRANSVENOUS EMBOLIZATION OF A CHALLENGING RUPTURED THALAMIC ARTERIOVENOUS MALFORMATION USING ONYX: CASE REPORT

## *Embolización curativa transvenosa de malformación arteriovenosa talámica rota compleja usando Onyx: Reporte de caso*

PAUL CARRANZA V.<sup>1a</sup>, WALTER DURAND C.<sup>2b</sup>, RICARDO VALLEJOS T.<sup>2b</sup>, DANTE VALER G.<sup>2b</sup>, JESÚS FLORES Q.<sup>2b</sup>, GIANCARLO SAAL-ZAPATA<sup>2b</sup>, RODOLFO RODRÍGUEZ V<sup>2b</sup>.

<sup>1</sup>Department of Neurosurgery Cayetano Heredia Hospital, <sup>2</sup>Department of Neurosurgery, Section of Neuroradiology of the Guillermo Almenara National Hospital, Lima, Perú. <sup>a</sup>Resident of Neurosurgery, <sup>b</sup>Endovascular Neurosurgeon

### ABSTRACT

**Introduction:** Arteriovenous malformations (AVM) are typically treated by arterial approach. In selected cases, venous embolization is an option with good results.

**Clinical case:** We present the case of a ruptured thalamic arteriovenous malformation treated successfully with transvenous embolization using Onyx, achieving complete obliteration of the nidus.

**Conclusion:** In selected cases, transvenous embolization is an option for the treatment of arteriovenous malformations

**Keywords:** Arteriovenous Malformation, Arteries, Embolization, Therapeutic, Polyvinyls. (source: MeSH NLM)

### RESUMEN

**Introducción:** Las malformaciones arteriovenosas son tratadas típicamente por abordaje arterial. En casos seleccionados, la embolización transvenosa es una opción con buenos resultados.

**Caso clínico:** Presentamos el caso de una malformación arteriovenosa talámica rota tratada exitosamente con embolización transvenosa usando Onyx, logrando una completa obliteración del nido.

**Conclusión:** En casos seleccionados, la embolización transvenosa es una opción para el tratamiento de malformaciones arteriovenosas.

**Palabras Clave:** Malformación Arteriovenosa, Arterias, Embolización Terapéutica, Polivinilos. (fuente: DeCS Bireme)

Peru J Neurosurg 2019, 1 (3): 69-72

**T**reatment of deep and ruptured arteriovenous malformations (AVM) is challenging and is associated to high risks. This is because of the proximity and participation of critical cerebral structures, therefore the fine and delicate angioarchitecture of these lesions making endovascular and surgical approach technically difficult. <sup>1,4</sup>

Transvenous approach is a concept that was developed initially for achieving cure in highly selected AVMs that cannot be accessed by arterial approach. <sup>1</sup>

The advent of Onyx has allowed a more controlled attempt of transvenous approach, it is a less adhesive embolic agent and can achieve a more controlled embolization, this allows more control with plug formation, nidus penetration and less reflux during treatments. <sup>3</sup>

We present a successful case of a patient with a challenging left thalamic AVM treated with Onyx by transvenous approach, achieving complete obliteration.

**Submitted:** January 06, 2019

**Accepted:** May 15, 2019

**HOW TO CITE THIS ARTICLE:** Carranza P, Durand W, Vallejos R, Valer D, Flores JQ, Saal-Zapata G, Rodríguez R. Curative transvenous embolization of a challenging ruptured thalamic arteriovenous malformation using Onyx: Case report. *Peru J Neurosurg* 2019; 1(3): 69-72

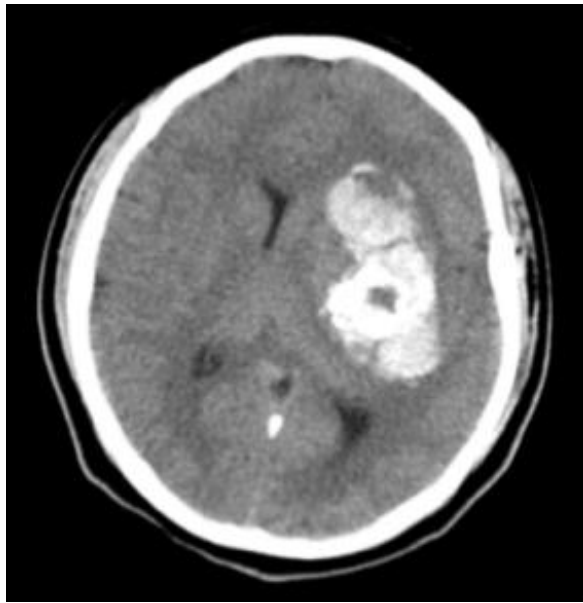


Fig 1. Brain CT. Ruptured left thalamic AVM

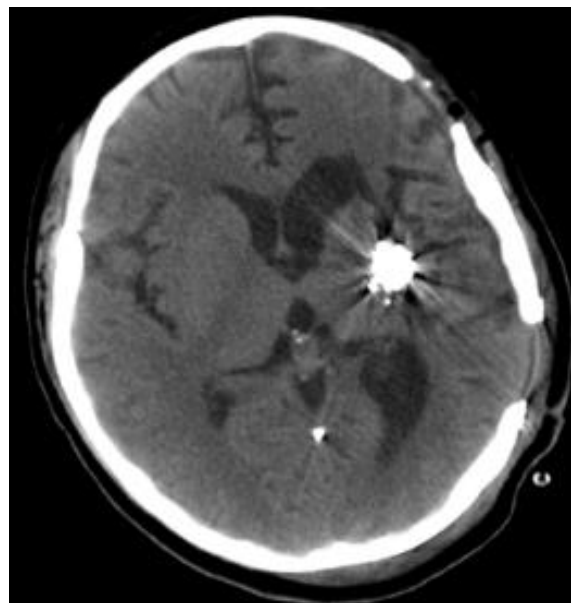

Fig 2. Brain CT after cranioplasty

## CLINICAL CASE

**History and clinical examination:** Fourteen-year-old female, presented ictus and digital subtraction angiography (DSA) revealing a left thalamic grade IV according to Spetzler-Martin classification. Partial embolization of AVM was performed, however, intraoperative ruptured (Figure 1) occurred and decompressive craniectomy was done (Figure 2).

Postoperative evolution was favorable and six months after the event, cranioplasty was performed with good clinical course. One-year follow-up DSA was performed showing ruptured left thalamic AVM with partial embolization (Figures 3A and 3B)

**Treatment:** Angiography identifies two feeding arteries arising from the thalamic-perforating arteries of the M1 segment of the middle cerebral artery (MCA) and a single stenosed vein draining in the basal vein of Rosenthal and straight sinus (Figure 3C and 3D).

Through right venous access we navigate with ENVOY 6F guide catheter into the jugular vein. With SONIC 1.5F microcatheter and HYBRID 007 microwire we navigate into the draining vein of the AVM and with ultra-selective injection we confirmed the correct position for the procedure. The embolization was performed with 1.8 ml of Onyx, with complete obliteration of the AVM (Figure 3F)

**Clinical evolution:** The patient evolved favorably in the postoperative period and was discharged 6 days later.

## DISCUSSION

Mendes et al found a high rate of anatomic cure by the transvenous approach (92.6%), using Onyx in most of the cases, showing viability of transvenous embolization for those AVMs previously not considered for this endovascular technique.<sup>1</sup>

He et al, immediately after transvenous embolization achieved a complete occlusion in 90% of cases and a residual nidus in 10% of cases.<sup>2</sup>

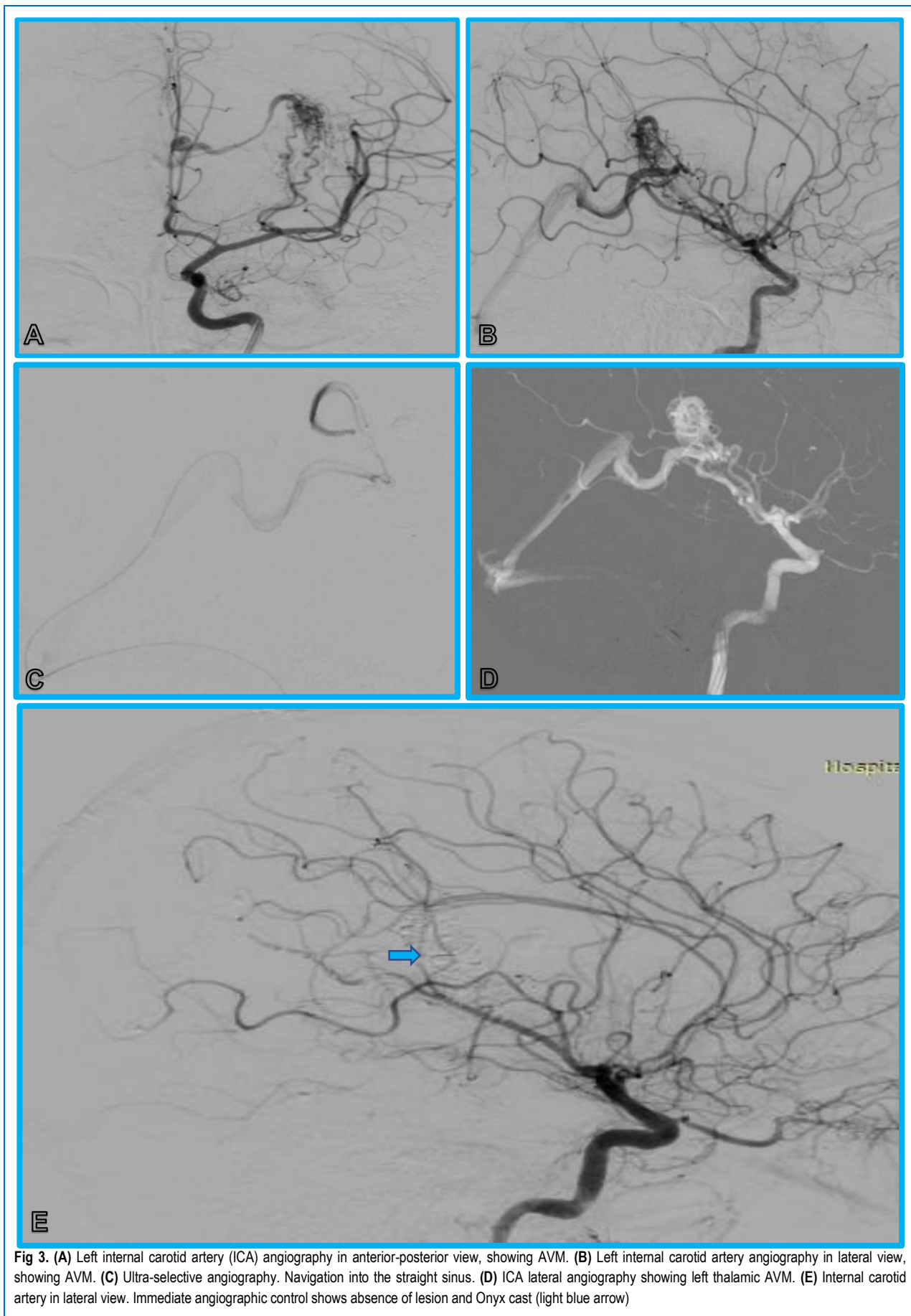
Kessler et al reached a high rate of nidus occlusion (80%) with insignificant morbidity and mortality. Moreover, concluded that Onyx 18 is a safe and efficient agent in the treatment of AVM using arterial and venous approaches.<sup>5</sup>

In our experience, transvenous approach is a safe and efficient option for treatment, here demonstrated in our case. We obtained an immediate postoperative angiographic control with total obliteration of the AVM. This is the reason that we consider that the transvenous route can achieve excellent results in patients, without impairment.

## CONCLUSION

Arteriovenous malformations can be treated successfully by a transvenous approach achieving high rates of complete obliteration with excellent functional results in patients with ruptured and non-ruptured AVMs.

This approach is promising and deserves more research for the treatment of this pathology. Moreover, Onyx is a safe and efficient embolic agent for the treatment of AVMs.



**Fig 3.** (A) Left internal carotid artery (ICA) angiography in anterior-posterior view, showing AVM. (B) Left internal carotid artery angiography in lateral view, showing AVM. (C) Ultra-selective angiography. Navigation into the straight sinus. (D) ICA lateral angiography showing left thalamic AVM. (E) Internal carotid artery in lateral view. Immediate angiographic control shows absence of lesion and Onyx cast (light blue arrow)

## REFERENCES

1. Mendes G, Kalani M, Losif C. Transvenous Curative Embolization of Cerebral Arteriovenous Malformations: A Prospective Cohort Study. **Neurosurgery**. 2017 Dec 21
2. He Y, Bai W, Li T, Hui FK. Curative Transvenous Embolization for Ruptured Brain Arteriovenous Malformations: A Single Center Experience from China. **World Neurosurg**. 2018 May 9
3. Choudhri O, Ivan ME, Lawton MT. Transvenous Approach to Intracranial Arteriovenous Malformations: Challenging the Axioms of Arteriovenous Malformation Therapy. **Neurosurgery**. 2015 Oct. 77(4):644-51
4. Kulcsár Z, Machi P. Transvenous embolization of a basal ganglia Ruptured Arteriovenous Malformation with Open Surgical Arterial Control: a Hybrid Technique. **Journal of Neuroradiology**, Volume 45, Issue 3, May 2018, Pages 202-205
5. Kessler I, Riva R, Ruggiero M, Manisor M. Successful transvenous embolization of brain arteriovenous malformations using Onyx in five consecutive patients. **Neurosurgery**. 2011 Jul;69(1):184-93

---

### Disclosures

The authors report no conflict of interest concerning the materials or methods used in this study or the findings specified in this paper.

### Author Contributions

*Conception and design:* All the authors. *Drafting the article:* Carranza. *Critically revising the article:* Rodríguez R. *Reviewed submitted version of manuscript:* Saal-Zapata. *Approved the final version of the manuscript on behalf of all authors:* Saal-Zapata.

### Correspondence

Paul Carranza Vasquez. Department of Neurosurgery. Cayetano Heredia National Hospital. 262 Honorio Delgado Avenue. SMP. Lima 31, Peru. E-mail: [paulcarranza13@gmail.com](mailto:paulcarranza13@gmail.com)